



HAL
open science

Assessment of TNF- α inhibitors in airway involvement of relapsing polychondritis

Josette Biya, Sandra Dury, Jeanne-Marie Perotin, Claire Launois, Maxime Dewolf, Gaetan Deslée, François Lebargy

► **To cite this version:**

Josette Biya, Sandra Dury, Jeanne-Marie Perotin, Claire Launois, Maxime Dewolf, et al.. Assessment of TNF- α inhibitors in airway involvement of relapsing polychondritis. *Medicine*, 2019, 98 (44), pp.e17768. 10.1097/MD.0000000000017768 . hal-02448785

HAL Id: hal-02448785

<https://hal.univ-reims.fr/hal-02448785v1>

Submitted on 2 Jun 2020

HAL is a multi-disciplinary open access archive for the deposit and dissemination of scientific research documents, whether they are published or not. The documents may come from teaching and research institutions in France or abroad, or from public or private research centers.

L'archive ouverte pluridisciplinaire **HAL**, est destinée au dépôt et à la diffusion de documents scientifiques de niveau recherche, publiés ou non, émanant des établissements d'enseignement et de recherche français ou étrangers, des laboratoires publics ou privés.

Assessment of TNF- α inhibitors in airway involvement of relapsing polychondritis

A systematic review

Josette Biya, MD^a, Sandra Dury, MD^{a,b}, Jeanne-Marie Perotin, MD, PhD^{a,c}, Claire Launois, MD^a, Maxime Dewolf, MD^a, Gaëtan Deslée, MD, PhD^{a,c}, François Lebargy, MD, PhD^{a,b,*}

Abstract

Relapsing polychondritis (RP) is a rare immune-mediated disease affecting cartilaginous structures. Respiratory tract manifestations are frequent and constitute a major cause of morbidity and mortality. The present review of the literature was designed to assess the efficacy of tumor necrosis factor alpha (TNF- α) inhibitors in respiratory tract involvement of RP.

A MEDLINE literature search was performed from January 2000 to December 2016 to identify all studies and case reports of anti-TNF- α therapy in RP. Articles published in English or French concerning patients with respiratory tract involvement were eligible. Two authors (JB, FL) independently reviewed and extracted data concerning each patient and 2 personal cases were added. Treatment efficacy was assessed according to systemic and/or respiratory criteria.

A total of 28 patients (mean age: 41.6 years; 16 females/12 males) were included in the final analysis. Anti-TNF- α therapy was associated with improved health status and respiratory symptoms in 67.8% and 60.1% of cases, respectively.

These results suggest that TNF- α inhibitors could be considered for the treatment of respiratory tract involvement of RP.

Abbreviations: CT = computed tomography, FDG/PET = fluorodeoxyglucose positron emission tomography, RP = relapsing polychondritis, TNF- α = tumor necrosis factor alpha.

Keywords: airways, relapsing polychondritis, TNF- α inhibitors

1. Introduction

Relapsing polychondritis (RP) is a rare immune-mediated disease affecting the cartilage of the nose, ears, tracheobronchial tree, peripheral joints, and proteoglycan-rich structures such as the inner ear, eyes, and cardiovascular system, mainly occurring during the 5th decade, with an equal sex ratio.^[1–5] The diagnosis of RP is based on the criteria established by McAdam in 1976, and modified in 1979 by Damiani and Levine^[1,2] (Table 1). The pathophysiology of RP is unclear, but potentially involves type II-collagen and matrilin-1.^[4] The target antigens remain unknown.

Respiratory manifestations occur in up to 50% of patients with RP and are a major source of morbidity and mortality.^[5–8] Systemic corticosteroid therapy is considered to be the

cornerstone of treatment. Immunosuppressive agents, such as methotrexate, azathioprine, cyclophosphamide, ciclosporin, and mycophenolate mofetil, are used as corticosteroid-sparing agents, or in the case of severe organ involvement.^[3,9] Biological agents, especially tumor necrosis factor alpha (TNF- α) inhibitors, have been considered as new treatment options. However, the exact impact of these treatments on airway involvement in RP has not been clearly determined. The present review of the literature was designed to assess the efficacy of TNF- α inhibitors in respiratory tract involvement of RP.

2. Methods

2.1. Literature search

A MEDLINE search of the English and French literature was performed to identify studies and cases reporting RP respiratory tract involvement and the use of TNF- α inhibitors. This search covered the period from the first use of anti-TNF- α therapy in January 2000 to December 2016. The following search terms were used: “Relapsing polychondritis,” “TNF-alpha blockers,” “TNF-alpha antagonists,” “TNF-alpha inhibitors” “anti-TNF-alpha,” “infliximab,” “etanercept,” “adalimumab,” “golimumab,” and “certolizumab.” We also searched for additional articles from the reference list of the relevant articles selected.

2.2. Inclusion criteria

Cases were selected when they met all of the following 3 criteria: Diagnosis of RP based on the criteria proposed by McAdam or Damiani and Levine (Table 1); Respiratory tract involvement reported as clinical symptoms (cough, dyspnea, hoarseness, stridor, bronchospasm, and laryngotracheal tenderness), and/or

Editor: Raffaele Pezzilli.

The authors have no funding and conflicts of interest to disclose.

^a Department of Respiratory Diseases, Reims University Hospital, ^b EA 4683 Medical and Pharmacological Sciences, ^c UMRS 903, Reims University Hospital, Reims, France.

* Correspondence: François Lebargy, Department of Respiratory Diseases, Reims University Hospital, 45, rue de Cognacq-Jay, 51092 Reims Cedex, France (e-mail: flebargy@chu-reims.fr).

Copyright © 2019 the Author(s). Published by Wolters Kluwer Health, Inc. This is an open access article distributed under the Creative Commons Attribution License 4.0 (CCBY), which permits unrestricted use, distribution, and reproduction in any medium, provided the original work is properly cited.

How to cite this article: Biya J, Dury S, Perotin JM, Launois C, Dewolf M, Deslée G, Lebargy F. Assessment of TNF- α inhibitors in airway involvement of relapsing polychondritis. *Medicine* 2019;98:44(e17768).

Received: 12 June 2019 / Received in final form: 26 September 2019 /

Accepted: 3 October 2019

<http://dx.doi.org/10.1097/MD.00000000000017768>

Table 1
Diagnostic criteria for relapsing polychondritis.
McAdam criteria (1): 3 or more of the following items
Auricular chondritis
Nasal chondritis
Respiratory tract chondritis
Nonerosive seronegative inflammatory polyarthritis
Ocular inflammation
Audiovestibular damage
Damiani and Levine criteria (2): any of the following items
Three or more of McAdam criteria
Two or more of McAdam criteria with therapeutic response to steroids and/or dapsone
One or more of McAdam criteria with positive histology on biopsy

obstructive defect on pulmonary function tests and/or tracheal or bronchial involvement (narrowing, thickening, stenosis or calcifications of the tracheal, and/or bronchial wall) on computed tomography (CT) scan and/or abnormal endoscopic findings (tracheomalacia, stenosis, and inflammation); and Use of 1 or more TNF- α inhibitors during the course of the disease. Articles were excluded when specific data could not be extracted. References were reviewed by 2 independent investigators (JB and FL). Decision for inclusion was based on a consensus involving a

3rd investigator (SD). Two previously unpublished personal cases were also added. In accordance with the Jardé law in France, access to patient data was approved by the French national commission for personal data protection (CNIL, Comité National de l'Information et des Libertés) (no 2049775 v 0) and informed consent for inclusion was waived because of the retrospective noninterventional design of this study and anonymous management of the patients' data.

2.3. Assessment criteria

Systemic response was defined by improvement of overall health status and/or clinical improvement of chondritis, and/or steroid sparing or withdrawal.

Respiratory response was defined as improvement of respiratory symptoms and/or pulmonary function tests and/or radiological findings and/or endoscopic features. Adverse events related to anti-TNF- α therapy were also reported.

3. Results

Figure 1 shows the flowchart of the selected articles.^[11–35] The final analysis was carried out on a total of 28 patients, including 2 unpublished personal cases.

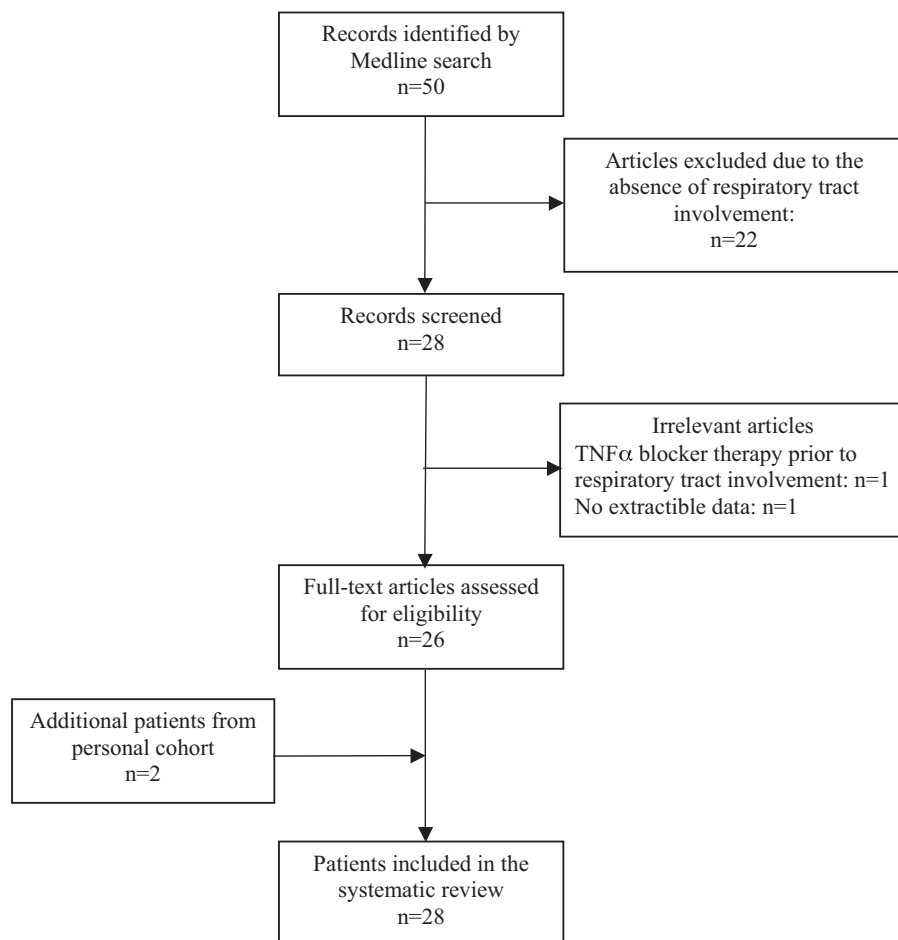


Figure 1. Patient selection flow chart.

Table 2**Demographic and clinical data.**

	Age, y	Sex	Associated disease	Respiratory symptoms	PFT	CT scan	FOB
Kraus ^[11]	18	M	None	Hoarseness Dyspnea ARF	Moderate bronchial hyperreactivity	Tracheal thickening and narrowing	NA
Mpofu ^[12]	51	F	None	Throat pain	Obstructive defect	Tracheal thickening	Laryngeal inflammation
Richez ^[13]	41	M	None	Dyspnea	NA	Pleural effusion	NA
Cazabon ^[14]	45	F	HLAB27+ AS	Laryngotracheal symptoms	NA	NA	NA
Ghosn ^[15]	7	F	None	Hoarseness	NA	NA	NA
Subrahmanyam ^[16]	54	F	None	Laryngeal tenderness Dyspnea	Obstructive defect	NA	Tracheomalacia
Kawai ^[17]	29	F	None	Dyspnea ARF	NA	Laryngotracheal walls thickening	NA
Marie ^[18]	38	F	None	Hoarseness	NA	NA	NA
Pamuk ^[19]	57	F	RA	Tracheal tenderness Laryngotracheal symptoms	NA	NA	NA
Ratzinger 1 ^[20]	56	F	None	Dyspnea	NA	Tracheal thickening	NA
Ratzinger 2 ^[20]	43	F	None	Dyspnea	NA	NA	NA
De Barros ^[21]	42	F	None	Hoarseness Dyspnea	NA	NA	NA
Buonuomo ^[22]	14	F	None	Throat Pain Hoarseness ARF	NA	Laryngotracheal inflammation	NA
Geissal ^[23]	34	M	Behçet's	Cough Hoarseness	Normal	Normal	NA
Lahmer ^[24]	69	M	None	Hoarseness	Obstructive/ Restrictive defect	NA	Tracheal and bronchial inflammation
Moullis ^[25]	49	F	None	Laryngeal tenderness Dyspnea	NA	NA	NA
Hernandez ^[26]	45	M	AS	Cough	Normal	Bronchial stasis	NA
Keidel ^[27]	66	M	None	Hoarseness	NA	NA	NA
Nakamura ^[28]	68	M	None	Asymptomatic	NA	Bilateral ground glass appearance	NA
Abdwan ^[29]	10	M	None	Stridor Dyspnea ARF	NA	Tracheal thickening and narrowing	Tracheal inflammation and narrowing Tracheomalacia
Adamson ^[30]	51	F	None	Cough Dyspnea Hoarseness	NA	Tracheal thickening and narrowing	Tracheomalacia
Fonseca ^[31]	6	F	None	Stridor Bronchospasm Dyspnea ARF	NA	NA	Subglottic stenosis
Wallace ^[32]	65	F	None	Tracheal tenderness Laryngeal symptoms	NA	NA	NA
Weber ^[33]	38	M	UC Hashimoto nAChR+/ID	Laryngeal symptoms	Obstructive defect	NA	NA
Henes ^[34]	27	M	None	Dyspnea	NA	NA	NA
Vitiello ^[35]	46	M	None	Cough	NA	NA	NA
Biya 1 (PD)	45	M	None	Hoarseness Dyspnea Cough Dysphonia	Obstructive defect	Tracheal calcifications	Tracheomalacia
Biya 2 (PD)	52	F	None	Hoarseness Cough ARF	Obstructive defect	Tracheal and bronchial thickening	Tracheal inflammation

ARF = acute respiratory failure, AS = ankylosing spondylitis, F = female, FOB = Fiberoptic bronchoscopy, M = male, NA = not available, nAChR+/ID = immune dysautonomia with presence of anti-nicotinic acetylcholine receptor antibody, PD = personal data, PFT = pulmonary function tests, RA = rheumatoid arthritis, UC = ulcerative colitis.

3.1. Demographic and respiratory features

Patient characteristics are presented in Table 2. Mean age at diagnosis was 41.6 years (6–69). Sixteen patients (57.1%) were women. Other concomitant autoimmune diseases were reported in 5 cases (17.8%). The most common manifestations were laryngeal symptoms (n=21, 75%) (hoarseness n=11, stridor n=2, dysphonia n=1, laryngeal tenderness n=2, or throat pain n=2, unspecified “laryngeal symptoms” n=4) and respiratory symptoms (n=21, 75%) (cough n=6, dyspnea n=13, tracheal tenderness n=2, bronchospasm n=1, unspecified “tracheal symptoms” n=2). Acute respiratory failure was reported in 6 patients (21.4%). Six of the 9 patients for whom pulmonary

function tests were available exhibited an obstructive pattern. Seven of the 13 patients investigated by CT scan presented tracheal thickening. Fiberoptic bronchoscopy was performed in 8 patients and revealed tracheomalacia (n=4), tracheal inflammation (n=3), or laryngeal inflammation and subglottic stenosis (n=2).

3.2. Drug regimen

All patients had previously received immunosuppressive agents, including steroids (100%), methotrexate (70%), cyclophosphamide (41%), azathioprine (22%), and rarely ciclosporin, mycophenolate mofetil, immunoglobulins, hydrochloroquine, tacrolimus, or rituximab (data not shown).

Table 3
Drug regimen.

	TNF- α inhibitor	Dosage	Concomitant treatment	Adverse effects	Duration
Kraus ^[11]	ETN	NA	CS-CP	NA	10 mo
	INF	NA	NA	NA	3 infusions
Mpofu ^[12]	INF	5 mg/kg	NA	None	>8 mo
Richez ^[13]	INF	5 mg/kg	CS	NA	>12 mo
Cazabon ^[14]	INF	3 mg/kg	NA	None	>6 mo
Ghosh ^[15]	INF	100 mg	CS	NA	9 cycles
Subrahmanyam ^[16]	INF	3–5 mg/kg	NA	Allergic reaction	3 infusions
	ETN	NA	CS		18 mo
Kawai ^[17]	INF	3 mg/kg	CS-MTX	NA	8 infusions
Marie ^[18]	INF	5 mg/kg	CS	NA	>36 mo
Pamuk ^[19]	ETN	25 mg \times 2/wk	CS-MTX-SLZ	NA	>24 mo
Ratzinger 1 ^[20]	INF	NA	NA	NA	>2 wk
Ratzinger 2 ^[20]	INF	NA	NA	NA	>24 mo
De Barros ^[21]	INF	3 mg/kg	CS-MTX	NA	>4 infusions
Buonuomo ^[22]	INF	5 mg/kg	CS	NA	3 infusions
Geissal ^[23]	INF	5 mg/kg	CS-MTX	NA	>34 mo
Lahmer ^[24]	ADA	40 mg/2 wk	CS	None	>3 mo
Moulis ^[25]	ADA	40 mg/2 wk	CS-MTX-Dapsone	NA	6 mo
	ETN	25 mg \times 2/wk	CS-MTX-Dapsone	NA	9 mo
	INF	3 mg/kg	CS-MTX-Dapsone	NA	10 mo
Hernandez ^[26]	ETN	25 mg \times 2/wk	CS-MTX	NA	>34 mo
Keidel ^[27]	ADA	40 mg/2 wk	CS-AZA	Sweet syndrome	1 infusion
	ETN	NA	NA	NA	NA
Nakamura ^[28]	ADA	40 mg/2 wk	CS-MTX	NA	>2 mo
Abdwani ^[29]	INF	5–10 mg/kg	CS-MTX	NA	6 mo
Adamson ^[30]	ADA	40 mg/2 wk	CS-MTX	NEM	1 infusion
Fonseca ^[31]	INF	NA	CS	“severe infusional reaction”	1 infusion
	ETN	NA	CS	NA	NA
Wallace ^[32]	INF	5 mg/kg	CS-CP	NA	9 mo
Weber ^[33]	INF	5 mg/kg	CS-MTX	NA	6 infusions
Henes ^[34]	ADA	40 mg/2 wk	CS-MTX	NA	2.5 mo
Vitiello ^[35]	INF	350 mg/5–8 wk	CS-MTX	NA	5 y
Biya 1 PD	INF	5 mg/kg	CS	None	24 mo
	ETN	25 mg/2 wk	CS	None	>36 mo
Biya 2 PD	INF	5 mg/kg	CS	None	4 mo

ADA = adalimumab, AZA = azathioprine, CP = cyclophosphamide, CS = steroids, ETN = etanercept, INF = infliximab, MTX = methotrexate, NA = not available, NEM = necrotizing eosinophilic myocarditis, PD = personal data, SLZ = sulfasalazine.

Infliximab, etanercept, and adalimumab were used in 75% ($n=21$), 28.6% ($n=8$), and 21.4% ($n=6$) of cases, respectively (Table 3). Six patients were treated with more than 1 TNF- α inhibitor due to adverse effects or lack of efficacy (11, 16, 25, 27, 31, Biya 1). Infliximab was administered at doses of 3 to 10 mg/kg/infusion, etanercept 25 mg was administered twice weekly by subcutaneous injection, and adalimumab 40 mg was administered once a fortnight. A TNF- α inhibitor was associated with other immunosuppressive agents, including steroids (100%), methotrexate (50%), cyclophosphamide (8.3%), azathioprine (4.2%), sulfasalazine (4.2%), or dapsone (4.2%) (data available for 24 patients) (Table 3).

Treatment duration reached 5 years for infliximab,^[35] 36 months for etanercept (Biya 1), and 6 months for adalimumab.^[25] Three patients received only 1 injection of anti-TNF- α inhibitor due to adverse effects.^[27,30,31]

3.3. Adverse effects of TNF- α inhibitors

Adverse effects are reported in Table 4. In 2 cases, infliximab caused a systemic or local hypersensitivity reaction leading to a switch from infliximab to etanercept in both cases.^[16,31] Infliximab induced an allergic chest reaction in 1 case with no impact on

treatment.^[16] Adalimumab therapy was complicated by an episode of Sweet syndrome requiring treatment discontinuation,^[27] and a case of fatal necrotizing eosinophilic myocarditis.^[30]

3.4. Assessment of the efficacy of anti-TNF- α therapy

Assessment of systemic manifestations after anti-TNF- α therapy was reported in all cases (Table 4). Nineteen of the 28 cases (67.8%) showed improvement of general health status (11–16, 18–21, 23–24, 26–28, 31, 35, Biya 1). Improvement of chondritis was reported in 13 out of 19 patients (68.4%) (13–16, 18–19, 21, 24, 26, 28–29, 35, Biya 1).

Respiratory assessment after anti-TNF- α therapy was available for only 25 patients (11–18, 20, 22, 24–35, Biya 1, Biya 2). Fifteen of these patients were improved (60%), but this assessment was only based on respiratory symptoms in 14 patients. Therefore, only 2 patients displayed respiratory improvement in terms of both symptoms and chest imaging and/or endoscopic features and/or PFT.^[11,12]

Fourteen patients were assessed for both ear/nose chondritis and respiratory tract. Among them, 12 patients had a similar response with an improvement in 7 patients and worsening in 5 patients.

Table 4
Assessment and efficacy of TNF- α inhibitors in RP.

	Improvement n, %
Systemic assessment (n=28)	19 (67.8)
Respiratory assessment (n=25)	15 (60)
Respiratory symptoms (n=23)	14 (60.1)
Imaging (n=7)	2 (28.6)
PFT (n=4)	1 (25)
Endoscopy (n=5)	1 (20)

PFT = pulmonary function tests, RP = relapsing polychondritis, TNF- α = tumor necrosis factor alpha.

4. Discussion

Respiratory tract involvement in RP occurs in up to 50% of patients during the course of the disease and is a leading cause of death due to airway collapse/narrowing and airway infections.^[5-7] Although epidemiological data suggest an equal gender distribution of RP, respiratory symptoms seem to be more frequent in women.^[5] Hoarseness and laryngeal tenderness over the thyroid cartilage and anterior trachea are the most common symptoms. Other symptoms include dry cough, dyspnea, inspiratory stridor, wheezing, and more rarely, hemoptysis.^[36,37] Airway stenosis is common and associated with airflow obstruction, as reported by Tillie-Leblond et al in 8 out of 9 patients with RP associated with respiratory symptoms.^[38] Assessment of expiratory and inspiratory flow-volume curves and airway resistance may be useful to identify the site and severity of the obstructive process.^[39] The characteristic findings on CT scan are thickening of tracheal and/or bronchial walls with sparing of posterior membrane, calcifications involving airway walls, and focal or diffuse airway stenosis.^[36,38,40] Dynamic expiratory CT scans demonstrate dynamic abnormalities in more than 90% of patients, including tracheomalacia and/or air trapping, although only half of them present inspiratory abnormalities.^[40] Bronchoscopy demonstrates abnormalities of the tracheobronchial tree in most patients, corresponding to mucosal inflammation, possibly associated with tracheal stenosis or total collapse of the trachea.^[36] Although well tolerated, bronchoscopy must be performed carefully due to the risk of severe airway collapse.^[38]

Few data are available concerning the associations between airway involvement and RP activity. Pathology findings suggest that the initial phase of the disease is characterized by inflammation of the tracheal wall with cartilage involvement leading to thickening and focal or diffuse airway stenosis. As the disease progresses, disruptions in the cartilage structure and fibrosis replacement lead to flabbiness and collapse of the airways.^[5] It is difficult to distinguish between respiratory symptoms related to acute flare of the disease and those related to airway destruction. The Relapsing Polychondritis Disease Activity Index (RPDAI) study group recently proposed a rating scale using 27 weighted items in order to provide objective means of assessment of disease activity.^[41] High weighted scores have been attributed to bronchial chondritis, but with no distinction between active inflammatory flares and irreversible destructive airway damage. Assessment of RP activity using fluorodeoxyglucose positron emission tomography (FDG/PET) could be a promising approach. In a retrospective study of 13 RP patients assessed by FDG/PET, 9 patients presented increased FDG uptake in the tracheobronchial tree, associated with CT abnormalities in every case.^[42] Decreased FDG uptake in upper and lower airways was also observed in 5 patients after treatment.^[43] However, further studies are needed to determine

the sensitivity and specificity of FDG/PET to assess airway involvement in RP.

A standardized treatment protocol has not been established due to the rarity of the disease. Current therapy is largely empiric and based on case reports. Steroids remain the mainstay during disease flares and as maintenance therapy at lower doses to prevent relapses. Severe forms of RP may require intravenous pulses of high-dose steroids or cyclophosphamide in addition to steroids. Immunosuppressants, such as methotrexate, azathioprine, dapsone, ciclosporin, mycophenolate, or intravenous immunoglobulin, have been proposed as steroid-sparing agents, but their efficacy has yet to be established. TNF- α inhibitors have been tested in many connective tissue diseases and have been shown to be effective in rheumatoid arthritis and ankylosing spondylitis, but few data are available in RP. In a recent systematic review of the literature comprising case reports and small series, infliximab was effective in 14 of 31 treated patients (45%), but ineffective in 13 patients (42%).^[10] A few patients were treated with etanercept (n=9) or adalimumab (n=4), successfully in 55% and 50% of cases, respectively.^[10] To our knowledge, this is the first study to assess the efficacy of TNF- α inhibitors on RP airway involvement. The results of this study demonstrate that TNF- α inhibitors are effective on systemic manifestations and respiratory involvement in 67.8% and 60.1% of cases, respectively. However, efficacy endpoints of biologics are poorly defined and differ from 1 case report to another. Of note in most cases, the efficacy of TNF- α inhibitors was assessed only on subjective respiratory symptoms. Indeed, some of them such as dyspnea, wheezing, or stridor cannot be used to distinguish laryngeal and tracheal involvement.

This study presents several limitations. Firstly, many data were missing for the cases selected in this systematic review. In 3 out of 28 cases, no information was available on respiratory follow-up after anti-TNF- α therapy. Furthermore, only 7 of the 13 patients investigated before treatment by chest CT scan were reassessed after treatment. Only 2 patients were assessed by FDG/PET. Interestingly, our patient did not show any tracheal ¹⁸FDG uptake on FDG/PET, but was improved by TNF- α inhibitors, with a reduction of symptoms, exacerbations, and hospitalizations. In the absence of objective criteria, response to treatment should therefore be interpreted with caution. Secondly, respiratory manifestations reported in 3 cases do not correspond to the specific airway disease usually related to RP. One patient had pleural effusion secondary to myocarditis,^[13] another had chronic obstructive pulmonary disease,^[24] and the last patient had a nonspecific ground glass appearance on CT scan.^[28] The efficacy of TNF- α inhibitors may therefore be overestimated in this systematic review. Thirdly, many patients received concomitant treatments that could interfere with TNF- α inhibitors. Airway investigations were rarely performed and were incomplete, preventing inflammatory lesions to be distinguished from irreversible airway damage. Systematic assessment of airway lesions in RP, including chest CT scan, pulmonary function test, and endoscopic investigation, would be useful.

5. Conclusion

Respiratory tract involvement is common in RP. Because of the rarity of this disease, no standardized treatment protocol is currently available. This review of the literature suggests the efficacy of TNF- α inhibitors on systemic and respiratory symptoms. However, this efficacy needs to be confirmed by more detailed case reports of respiratory involvement.

Author contributions

Conceptualization: Josette Biya, Sandra Dury, Jeanne-Marie Perotin, Maxime Dewolf, Claire Launois, Gaëtan Deslée, Francois Lebargy.

Data curation: Josette Biya, Sandra Dury, Francois Lebargy.

Formal analysis: Josette Biya, Sandra Dury, Francois Lebargy.

Methodology: Josette Biya, Sandra Dury, Francois Lebargy.

Project administration: Josette Biya, Sandra Dury, Francois Lebargy.

Supervision: Josette Biya, Sandra Dury, Gaëtan Deslée, Francois Lebargy.

Validation: Josette Biya, Sandra Dury, Francois Lebargy.

Visualization: Josette Biya, Sandra Dury, Jeanne-Marie Perotin, Maxime Dewolf, Claire Launois, Gaëtan Deslée, Francois Lebargy.

Writing – original draft: Josette Biya, Sandra Dury, Jeanne-Marie Perotin, Maxime Dewolf, Claire Launois, Gaëtan Deslée, Francois Lebargy.

Writing – review & editing: Josette Biya, Sandra Dury, Francois Lebargy.

References

- McAdam LP, O'Hanlan MA, Bluestone RCM, et al. Relapsing polychondritis: prospective study of 23 patients and a review of the literature. *Medicine (Baltimore)* 1976;55:193–215.
- Damiani JM, Levine HL. Relapsing polychondritis. Report of ten cases. *Laryngoscope* 1979;89:929–46.
- Letko E, Zafirakis P, Baltatzis S, et al. Relapsing polychondritis: a clinical review. *Semin Arthritis Rheum* 2002;31:384–95.
- Arnaud L, Mathian A, Haroche J, et al. Pathogenesis of relapsing polychondritis: a 2013 update. *Autoimmun Rev* 2014;13:90–5.
- Cantarini L, Vitale A, Brizi MG, et al. Diagnosis and classification of relapsing polychondritis. *J Autoimmun* 2014;48–49:53–9.
- Michet CJ, McKenna CH, Luthra HS, et al. Relapsing polychondritis. Survival and predictive role of early disease manifestations. *Ann Intern Med* 1986;104:74–8.
- Eng J, Sabanathan S. Airway complications in relapsing polychondritis. *Ann Thorac Surg* 1991;51:686–92.
- Carrión M, Girón JA, Ventura J, et al. Airway complications in relapsing polychondritis. *J Rheumatol* 1993;20:1628–9.
- Lahmer T, Treiber M, von Werder A, et al. Relapsing polychondritis: an autoimmune disease with many faces. *Autoimmun Rev* 2010;9:540–6.
- Kemta Lekpa F, Kraus VB, Chevalier X. Biologics in relapsing polychondritis: a literature review. *Semin Arthritis Rheum* 2012;41:712–9.
- Kraus VB, Stabler T, Le ET, et al. Urinary type II collagen neopeptide as an outcome measure for relapsing polychondritis. *Arthritis Rheum* 2003;48:2942–8.
- Mpofu S, Estrach C, Curtis J, et al. Treatment of respiratory complications in recalcitrant relapsing polychondritis with infliximab. *Rheumatology* 2003;42:1117–8.
- Richez C, Dumoulin C, Coutouly X, et al. Successful treatment of relapsing polychondritis with infliximab. *Clin Exp Rheumatol* 2004;22:629–31.
- Cazabon S, Over K, Butcher J. The successful use of infliximab in resistant relapsing polychondritis and associated scleritis. *Eye* 2005;19:222–4.
- Ghosn S, Malek J, Shbaklo Z, et al. Takayasu disease presenting as malignant pyoderma gangrenosum in a child with relapsing polychondritis. *J Am Acad Dermatol* 2008;59:584–7.
- Subrahmanyam P, Balakrishnan C, Dasgupta B. Sustained response to etanercept after failing infliximab, in a patient with relapsing polychondritis with tracheomalacia. *Scand J Rheumatol* 2008;37:239–40.
- Kawai M, Hagihara K, Hirano T, et al. Sustained response to tocilizumab, anti-interleukin-6 receptor antibody, in two patients with refractory relapsing polychondritis. *Rheumatology* 2009;48:318–9.
- Marie I, Lahaxe L, Josse S, et al. Sustained response to infliximab in a patient with relapsing polychondritis with aortic involvement. *Rheumatology (Oxford)* 2009;48:1328–9.
- Pamuk ÖN, Harmandar F, Çakir N. The development of trigeminal neuralgia related to auricular chondritis in a patient with rheumatoid arthritis – relapsing polychondritis and its treatment with etanercept. Description of first case. *Clin Exp Rheumatol* 2009;27:128–9.
- Ratzinger G, Kuen-Spiegl M, Sepp N. Successful treatment of recalcitrant relapsing polychondritis with monoclonal antibodies. *J Eur Acad Dermatol Venereol* 2009;23:474–5.
- de Barros AP, Nakamura NA, Santana Tde F, et al. Infliximab in relapsing polychondritis. *Rev Bras Reumatol* 2010;50:211–4.
- Buonuomo PS, Bracaglia C, Campana A, et al. Relapsing polychondritis: new therapeutic strategies with biological agents. *Rheumatol Int* 2010;30:691–3.
- Geissal ED, Wernick R. A case of severe MAGIC syndrome treated successfully with the tumor necrosis factor-alpha inhibitor infliximab. *J Clin Rheumatol* 2010;16:185–7.
- Lahmer T, Knopf A, Treiber M, et al. Treatment of relapsing polychondritis with the TNF-alpha antagonist adalimumab. *Clin Rheumatol* 2010;29:1331–4.
- Moulis G, Sailler L, Astudillo L, et al. Abatacept for relapsing polychondritis. *Rheumatology (Oxford)* 2010;49:1019.
- Hernández MV, Ruiz-Esquide V, Gómez-Caballero ME, et al. Relapsing polychondritis: a new adverse event secondary to the use of tumour necrosis factor antagonists? *Rheumatology (Oxford)* 2011;50:1523–5.
- Keidel S, McColl A, Edmonds S. Sweet's syndrome after adalimumab therapy for refractory relapsing polychondritis. *BMJ Case Rep* 2011;pii: bcr1020114935.
- Nakamura H, Suzuki T, Nagaoka K, et al. Efficacy of adalimumab for a refractory case of relapsing polychondritis with reduction of pro-inflammatory cytokines. *Mod Rheumatol* 2011;21:665–8.
- Abdwan R, Kolethekkat AA, Al Abri R. Refractory relapsing polychondritis in a child treated with antiCD20 monoclonal antibody (rituximab): first case report. *Int J Pediatr Otorhinolaryngol* 2012;76:1061–4.
- Adamson R, Yazici Y, Katz ES, et al. Fatal acute necrotizing eosinophilic myocarditis temporally related to use of adalimumab in a patient with relapsing polychondritis. *J Clin Rheumatol* 2013;19:386–9.
- Fonseca AR, De Oliveira SKF, Rodrigues MCF, et al. Relapsing polychondritis in childhood: three case reports, comparison with adulthood disease and literature review. *Rheumatol Int* 2013;33:1873–8.
- Wallace ZS, Stone JH. Refractory relapsing polychondritis treated with serial success with interleukin 6 receptor blockade. *J Rheumatol* 2013;40:100–1.
- Weber E, Gaultier J-B, Paul S, et al. Sustained response with tocilizumab in a case of refractory relapsing polychondritis. *Rev Med Interne* 2014;35:196–8.
- Henes JC, Xenitidis T, Horger M. Tocilizumab for refractory relapsing polychondritis-long-term response monitoring by magnetic resonance imaging. *Joint Bone Spine* 2016;83:365–6.
- Vitiello G, Palterer B, Parronchi P, et al. Tocilizumab-induced mucosal ulcers in a patient with relapsing polychondritis: an adverse drug reaction? *Semin Arthritis Rheum* 2016;46:e9–10.
- Ernst A, Rafeq S, Boiselle P, et al. Relapsing polychondritis and airway involvement. *Chest* 2009;135:1024–30.
- Hong G, Kim H. Clinical characteristics and treatment outcomes of patients with relapsing polychondritis with airway involvement. *Clin Rheumatol* 2013;32:1329–35.
- Tillie-Leblond I, Wallaert B, Leblond D, et al. Respiratory involvement in relapsing polychondritis: clinical, functional, endoscopic, and radiographic evaluations. *Medicine (Baltimore)* 1998;77:168–76.
- Mohsenifar Z, Tashkin DP, Carson SA, et al. Pulmonary function in patients with relapsing polychondritis. *Chest* 1982;81:711–7.
- Lee KS, Ernst A, Trentham DE, et al. Relapsing polychondritis: prevalence of expiratory CT airway abnormalities. *Radiology* 2006;240:565–73.
- Arnaud L, Devilliers H, Peng SL, et al. The Relapsing Polychondritis Disease Activity Index: development of a disease activity score for relapsing polychondritis. *Autoimmun Rev* 2012;12:204–9.
- Yamashita H, Takahashi H, Kubota K, et al. Utility of fluorodeoxyglucose positron emission tomography/computed tomography for early diagnosis and evaluation of disease activity of relapsing polychondritis: a case series and literature review. *Rheumatology (Oxford)* 2014;53: 1482–90.
- Wang J, Li S, Zeng Y, et al. 18F-FDG PET/CT is a valuable tool for relapsing polychondritis diagnosis and therapeutic response monitoring. *Ann Nucl Med* 2014;28:276–84.