



**HAL**  
open science

## Surgical treatment of terrible triad of the elbow

Xavier Ohl, Renaud Siboni

► **To cite this version:**

Xavier Ohl, Renaud Siboni. Surgical treatment of terrible triad of the elbow. *Orthopaedics & Traumatology: Surgery & Research*, 2021, 107 (1), pp.102784. 10.1016/j.otsr.2020.102784 . hal-03591775

**HAL Id: hal-03591775**

**<https://hal.univ-reims.fr/hal-03591775>**

Submitted on 13 Feb 2023

**HAL** is a multi-disciplinary open access archive for the deposit and dissemination of scientific research documents, whether they are published or not. The documents may come from teaching and research institutions in France or abroad, or from public or private research centers.

L'archive ouverte pluridisciplinaire **HAL**, est destinée au dépôt et à la diffusion de documents scientifiques de niveau recherche, publiés ou non, émanant des établissements d'enseignement et de recherche français ou étrangers, des laboratoires publics ou privés.



Distributed under a Creative Commons Attribution - NonCommercial 4.0 International License

**Review article (Surgical technique)**

**Surgical treatment of terrible triad of the elbow**

Xavier **Ohl**<sup>1</sup>, Renaud **Siboni**<sup>1</sup>

<sup>1</sup>Service d'Orthopédie-Traumatologie. Hôpital Maison-Blanche, 45 Rue Cognacq-Jay, 51100 REIMS, France

**Corresponding author:**

Pr Xavier OHL  
Service d'Orthopédie-Traumatologie.  
Hôpital Maison-Blanche  
45 Rue Cognacq-Jay  
51100 REIMS, France  
xohl@chu-reims.fr

**Abstract**

Terrible triad of the elbow associates posterior dislocation, radial head fracture and coronoid process fracture. It is a complex trauma, associating severe bone and ligament lesions, with high more-or-less long-term risk of residual instability, stiffness, pain and osteoarthritis. During the last 20 years, pathologic, biomechanical and clinical knowledge has greatly progressed. Prevention of these severe complications requires initial understanding of the lesion mechanism and precise analysis of all lesions. Surgery aims to restore perfect stability by sequential anatomic repair, enabling early mobilization to prevent onset of stiffness.

The aims of the present paper were to summarize the anatomic and pathophysiological bases, highlight the crucial importance of the humeroradial column and lateral collateral ligament, and to determine the importance of the coronoid process. Some aspects of treatment are controversial: systematic medial collateral ligament repair, or use of an articulated external fixator. Finally, we propose a simple algorithm to guide repair.

Keywords: elbow; dislocation; terrible triad; radial head; coronoid process

## Introduction

Terrible triad (TT) is a frequent and highly unstable form of fracture-dislocation of the elbow associating posterior dislocation of the elbow, radial head fracture and coronoid process fracture. Management needs to be well codified to avoid definitive complications, the most frequent of which are stiffness, especially in extension, and residual instability, especially posterolateral.

Treatment aims to restore perfect stability to allow rapid mobilization of the joint.

The present paper seeks to answer the following questions:

- Why is this triad so terrible, and how should lesions be assessed?
- How should the radial head be managed?
- Should the coronoid process be repaired, and if so how?
- In what order should ligaments be repaired?
- What is the role of external fixation?
- What are the results of the various treatment options?

### 1. Why is this triad so terrible, and how should lesions be assessed?

#### 1.1 Lesion mechanism

TT is a form of elbow dislocation associating posterior or posterolateral humeroulnar dislocation with radial head fracture and coronoid process fracture due to posterolateral trauma with the hand in pressure and the forearm in compression under the humerus. The dislocating force combines forearm rotation (supination) and valgus. Dislocation is simple if the rotation is enough for the radial head and coronoid process to be brought under the distal humerus; otherwise, impact on the distal humerus fractures the radial head and coronoid process [1]. The first compartment to be affected is lateral, with lateral collateral ligament (LCL) lesion. Forces are then transmitted to the anterior and posterior capsule and then the medial collateral ligament (MCL) [2] (Figure 1).

The association impacts all elbow stabilizers: primary (LCL, MCL) and secondary (radial head and humeroradial joint, and anterior capsule fixed on the coronoid process).

#### 1.2 Initial treatment

Complete clinical examination screens for cutaneous and neurovascular complications. Standard AP and lateral X-ray confirms diagnosis and detects any bone fragments from the radial head, coronoid process or medial or lateral epicondyle. Elbow CT should be performed after reduction to visualize fragments and plan treatment. The wrist should be systematically examined to screen for pain and/or distal radioulnar joint deformity, and comparative bilateral radiographs should screen for Essex-Lopresti syndrome.

Reduction uses external maneuvers under fluoroscopy, with the patient under anesthesia in the operating room. General anesthesia is to be preferred, to obtain complete muscle relaxation and as operative time can be hard to predict, and allows postoperative neurologic surveillance, unlike peripheral nerve block.

When reduction has been achieved, elbow stability can be assessed, notably in extension. In some rare cases of TT with non-displaced radial head fracture and fracture of the tip of the coronoid, non-operative treatment may be indicated if the elbow is stable on testing [3]. If on the other hand the joint dislocates in 45° extension, it needs to be stabilized. “Too good” a joint line on post-reduction radiographs also suggests possible residual instability.

Surgical strategy is codified. It should begin with a lateral approach to expose and detail lesions “from outside inward” (LCL, radial head, coronoid process), then repair them “from inside outward”. Some authors recommend a single posterior approach, giving simultaneous access to both compartments.

### 1.3 Lateral approach

The patient is positioned supine, with the operated limb on a table and a pneumatic tourniquet. We use the lateral Kocher approach rather than Cadenat posterolateral approaches, as there is generally no need for downward extension, which would risk damaging the deep branch of the radial nerve. The lateral approach provides better access to the coronoid process than do posterolateral approaches. The skin landmarks comprise the lateral epicondyle and the radial head (or neck), located under pronation-supination. All lateral approaches come close to the radial nerve, which has to be borne in mind throughout surgery; pronation tends to move the nerve and its branches out of the way.

Skin incision is vertical, about 5 cm above the lateral epicondyle, then curving at the lateral epicondyle and following the lateral side of the forearm down to the radial neck. The muscle fascia incision is between the carpal ulnar extensor and the anconeus muscle. In practice, the fascial tear induced by the trauma is often used (Figure 2). At this point, the hemarthrosis evacuates through the lateral capsule-ligament detachment, which should be extended down toward the annular ligament, which is then sectioned and located, to be repaired at end of surgery. Proximally, the proximal LCL is usually found to be detached and the lateral epicondyle to be bare (Figure 3). Intra-ligament tear and distal detachment are rarer.

After washing out the hemarthrosis, the humeroradial and humeroulnar joints can be explored for lesion assessment: although X-ray or CT investigate fractures, cartilage lesions, which are just as important, often need screening at this point, and are detailed in the surgery report.

### 1.4 Single posterior approach

This is an extensive approach, although medial compartment access is in fact seldom needed. We therefore do not use it in first line. It requires lateral decubitus positioning with arm in 90° flexion on a support.

#### **To sum up:**

- TT is a severe and complex elbow trauma involving both bone and ligament elements.

- Reduction is performed in theater, and post-reduction CT is necessary to analyze bone lesions. After reduction, surgery is indicated in case of instability in extension.
- A single lateral approach is often sufficient.

## 2. How should the radial head be managed?

In non-displaced radial head fracture, non-operative treatment is indicated [3]. In displaced or comminuted fracture, treatment is surgical. Radial head resection is to be avoided, and the choice is between internal fixation or prosthesis. Comminution, patient age and bone quality are determining factors in this choice.

### 2.1 Internal fixation

Internal fixation is feasible if there are no more than 3 fragments and if there is bone continuity between part of the radial head and the neck. Simple screwing is the most common technique.

All radial head fragments must be located; if one is missing, it needs to be found under fluoroscopy. Once all have been found, temporary K-wire fixation can be performed. Definitive fixation uses intra-osseous screws and/or screws in compression (Figure 4). If fixation is insufficiently stable, low-profile anatomic plates specific to the radial head can be used, requiring a more extensive approach to the neck, with risk of injuring the posterior interosseous nerve. This plate needs to be positioned in the safe zone of the radial head and neck surface seen on the lateral approach with the forearm in neutral pronation (Figure 5).

In case of radial neck fracture and intact but impacted radial head, the technique of choice is retrograde pinning to raise the head.

### 2.2 Prosthesis

When internal fixation is not possible, resection is to be avoided due to risk of Essex-Lopresti syndrome and residual posterolateral instability [4]. Radial head replacement is then needed, to reconstruct the humeroradial column. Various parameters have to be taken into account in choosing the type and positioning of the implant.

#### 2.2.1 *Type of implant*

Choice is based on intra-prosthetic mobility, type of stem fixation, and implant modularity.

- In traumatology, a fixed head is preferred, restoring better stability than bipolar implants with intra-prosthetic mobility, as shown in-vitro [5] and in-vivo [6].
- There are several types of fixation: cementless, cemented, and “mobile” within the medullary canal. Cemented implants are interesting, but there is “no going back” in case of error in height. With uncemented implants, it is difficult to use a press-fit technique in small-diameter bone, due to risk of fracture. Some manufacturers provide a compression screw to stabilize the stem in the medullary canal. An unfixed stem “floating” in the canal theoretically allows implant alignment to be adapted in movement, but with risk of residual elbow pain [1].

- c) The main argument concerns implant modularity, enabling in-situ choice of the best combination of head, neck and stem to optimize stability, avoiding impingement and allowing optimal implant positioning.

### 2.2.2 Positioning

Good implant positioning determines efficacy and joint congruence. The relevant factors are head diameter, implant height and congruence on fluoroscopy.

- a) Head diameter is selected on a simple rule. Head fragments are collected and reassembled on the table to get a precise idea of native head diameter. Too small a prosthetic head gives too narrow a contact area with the capitulum and incomplete LCL tensioning. Too large a head incurs risks of “overstuffing” and poor congruence between the implant and the ulnar sigmoid cavity, excessive LCL tension, and postoperative stiffness. In case of hesitation between two sizes, the smaller should be chosen.
- b) Most present-day implants allow height to be adjusted independently of head diameter. Thus, dynamic tests and fluoroscopic control on a trial implant are essential. Two radiographic criteria help optimize positioning: implant head height should not exceed the inferior edge of the ulnar groove on AP view in extension; and the humeroulnar space should be medially and laterally symmetrical [4]. Fluoroscopic views of the wrist should also be taken in case of suspected Essex-Lopresti syndrome.

Recent but contradictory meta-analyses compared internal fixation versus head replacement in TT [7-9]. At all events, all radial head internal fixation methods and a total radial head prosthesis need to be available in theater.

#### **To sum up:**

- Radial head resection is never indicated. Internal fixation or replacement is the rule, as it is essential to reconstruct the humeroradial column.
- The gold standard in internal fixation is compression screwing.
- Radial head replacement has to be rigorous to avoid residual instability or overstuffing.
- Wrist X-ray screening for Essex-Lopresti syndrome should be performed in case of the slightest doubt.

## **3. Should the coronoid process be repaired, and if so how?**

### 3.1 Pathophysiology and classifications of coronoid process fracture

Coronoid process repair is presently the center of controversy. The coronoid process contributes to stability by contributing to bone surface congruence; anatomic studies showed that the elbow cannot be stable in case of fracture detaching >50% of the coronoid process surface. It is also the insertion site for the main (anterior) MCL bundle and also for the anterior capsule and the anterior brachial muscle, which also contribute to stability.

Coronoid process fracture classification progresses regularly. Regan and Morrey's was the first classification, based on standard AP views, in 3 grades: grade 1, coronoid tip; grade

2, <50%; and grade 3, >50% of the coronoid process [10] (Figure 6). O'Driscoll et al. proposed a new classification, based on 3D and CT analysis of the fracture line [11], distinguishing tip (type 1), anteromedial (type 2) and base (type 3) fracture (Figure 6).

New anatomic studies [12] analyzed the contributions of the coronoid process and the radial head to stability. All agreed that base fracture (type 3) should be stabilized. In other cases, stabilization is necessary only if stability is not restored after radial head reconstruction and fixation of the lateral capsule-ligament complex. There are various means of stabilization, choice depending on type of coronoid fracture, approach, and type of radial head fracture.

### 3.2 When the radial head cannot be conserved

In this case, access to the coronoid process is facilitated by a lateral approach after resecting the radial neck. We often perform coronoid bone suture in type 1 or 2 fracture, using a metal anchor in the fracture site or, preferably, using posteroanterior bone tunnels with posterior lacing. In type 3 fracture with a large fragment, we prefer a cannulated screw under visual and fluoroscopic control.

*Bone suture* via bone tunnels can easily be performed on a lateral approach when the radial head is resected. The first step consists in lacing the coronoid tip with non-absorbable suture, taking care to have a sufficient length of each thread to be able to pass them through the tunnels and tie them behind. The tunnels can be performed with the help of a knee ligament reconstruction visor to control the exit into the fracture site. We prefer to drill two parallel 2-mm tunnels, then using straight suture-passers to bring out the two strands at the ulnar crest. The two strands are then held by forceps on stand-by, as definitive fixation of the coronoid process has to await radial head implantation. Coronoid process suturing is performed on the reduced elbow in 90° flexion.

*Internal fixation by cannulated screw*, posterior to anterior, is also quite simple. The screws have to be long enough and 3-4 mm in diameter. Reduction often uses a spatula or small pointed forceps while positioning 1 or 2 K-wires from posterior to anterior under fluoroscopic control. If K-wire positioning is correct, drilling and screw positioning can proceed. Using 2 cannulated screws is mechanically preferable, but seldom possible given coronoid fragment size.

### 3.3 When the radial head is conserved

After internal fixation of the radial head, the remaining unfractured part restricts coronoid process access. In that case, we do not systematically fix the coronoid process in Regan-Morrey types 1 and 2. Elbow testing after head fixation and lateral capsule-ligament suture guides any complementary coronoid process fixation, which in fact we find rarely necessary. In type 3, the coronoid process can be reduced on a lateral approach even when the radial head has been conserved, by screwing under fluoroscopy.

A second approach (pure anterior or medial) can be necessary for coronoid process fixation by direct screwing or using a dedicated anatomic plate. A medial approach [13] involves prior location of the ulnar nerve and medial ligament repair in addition to coronoid process fixation. The anterior approach is more delicate technically, and allows only fixation of the coronoid process [14, 15] (Figures 7A and 7B).



Systematic fixation of the coronoid process is controversial [16, 17]. Papatheodorou et al. [18] reported excellent clinical and radiological results in 14 TTs treated by isolated fixation or replacement of the radial head and lateral suturing. The coronoid fractures were type 1 or 2, with no type 3s, and were never fixed. This report confirmed the in-vitro findings reported by Jeon et al. [12], who recommended fixation essentially of type 3 fracture.

**To sum up:**

- Type 3 coronoid process fracture should be systematically fixed.
- In types 1 and 2, the choice depends on whether the radial head is conserved and on elbow stability after reconstructing the humeroradial column and lateral ligament.

**4. In what order should ligaments be repaired?**

In TT, the lateral ligament is always involved, whereas the medial ligament may be intact [1]. Lateral repair is systematic and constitutes the final step in the lateral approach; medial repair is rarely necessary.

**4.1 LCL repair**

The LCL is usually detached from the lateral epicondyle, which is “bare”, due to this proximal detachment. Sometimes the ligament is torn in its body, or, more rarely, detached distally, in which case direct suture or distal reinsertion on the ulna is required. The lateral ligament complex ensures stability in varus and posterolateral stability. For recent lesions, LCL repair is usually enough; reconstruction can be considered in case of posterolateral instability persisting some time after trauma.

The classic technique consists in bone suture or, more often, anchors fixed on the lateral epicondyle. This allows permanent control of suture tension and the elbow to be cycled ahead of definitive suture [19]. We usually use 2 metal anchors impacted on the epicondylar crest (Figure 8). Mason-Allen sutures are then performed to fix the capsule-ligament and tendon on the lateral epicondyle (Figure 9). After complete reduction, the elbow is put in 90° flexion in neutral pronation-supination, and the knots are tightened. The annular ligament is then sutured with absorbable sutures.

**4.2 MCL repair**

In our experience, this step is rarely necessary, but it is important to know when and how it should be undertaken. Like for the LCL, the MCL is usually detached from its humeral insertion. In TT, it is by definition associated with coronoid process fracture.

If the elbow is still unstable in extension after coronoid fixation, head fixation or replacement and lateral ligament repair, the medial ligament has to be repaired. Isolated frontal instability in valgus, on the other hand, without instability in flexion-extension does not require MCL repair [20].

The medial approach is centered on the medial epicondyle, to explore and release the ulnar nerve. The medial epicondyle is found to be bare, and MCL repair is performed like for the LCL, with non-absorbable anchors. If the coronoid process needs to be accessed, it is sufficient to release and retract the medial epicondylar and anterior brachial muscles forward to give access to the anteromedial capsule and the coronoid process.

A recent retrospective study comparing a single lateral approach and a double lateral plus medial approach [21] found much better clinical results and fewer complications (notably concerning the ulnar nerve) in the former.

#### 4.3 Postoperative course

Once stability has been restored, the usually recommended 6 weeks' cast immobilization is superfluous. We prescribe 10 days' long-arm contention (resin or made-to-measure rigid splint) then, after a radiological and clinical check-up on day 10, an articulated elbow orthosis allowing free pronation-supination, set for 2 weeks in 120° flexion and 45° extension; at 1 month, ranges of motion are increased. After 6 weeks, the orthosis is discarded after a radiographic check. The patients then perform self-rehabilitation associating flexion-supination and extension-pronation.

#### **To sum up:**

- Lateral ligament repair is fundamental, and should be systematic on a lateral approach.
- Medial ligament repair should not be systematic, but reserved to cases of instability in extension persisting after lateral repair.

### **5. What is the role of external fixation?**

If, after all lesions have been repaired, the elbow is still unstable in flexion-extension, an articulated (dynamic) external fixator may be considered [22]. In our experience, this is exceptional, and repair quality should be checked first. Some authors advocate first-line articulated external fixation ahead of medial repair [16]. Whatever the case, transarticular ulnohumeral pinning is not indicated.

A recent multicenter prospective study specified the role of external fixation and the expected results [23], in 27 patients (9 TTs) with external fixation following elbow reduction and lesion repair. Results were excellent, but the authors stressed the difficulty of achieving perfect joint congruence, essential for rapid mobilization.

#### **To sum up:**

- If, after repairing the various bone and ligament structures, the elbow is still unstable in extension, an articulated external fixator may be considered.
- The technique has to be rigorous, to achieve good joint congruence.
- We propose a decision-tree for TT treatment after lesion assessment (Figure 10).

### **6. What are the results of the various treatment options?**

#### 6.1 What results can be expected?

The first clinical series reported catastrophic results, greatly contributing to the notoriety of TT [24-27]. Associated complications include residual instability, stiffness, persistent pain and humeroulnar and/or humeroradial osteoarthritis [28].

These poor early results were due to lack of knowledge of the pathology and biomechanical consequences of the lesions. Many biomechanical studies have since been conducted and standardized protocols have been designed [11, 18, 24-27, 29-31]. The radial head is now systematically reconstructed or replaced and the lateral ligaments are reinserted, both being requirements for good outcome (Figure 11A-G). It is always essential to restore elbow stability at end of procedure, allowing very early mobilization to prevent rapid severe stiffening.

In a recent review of the literature, Chen et al. [28] found satisfactory clinical scores and MEPS (Mayo Elbow Performance Score) 78-95/100. However, the revision surgery rate was 22%, due to hardware-related complications, stiffness, instability, and ulnar neuropathy. A recent study reported long-term results at a mean 9 years in 12 cases treated by the standardized procedure described here [32]. Clinical results were very encouraging, with a mean 151° flexion-extension and 162° pronation-supination, but with osteoarthritic remodeling in 66% of cases.

## 6.2 What factors affect results?

Zhou et al. [33] analyzed the impact of time to treatment in a retrospective study, with 3 groups: treatment within 24 hours, at 2-14 days, and >14 days. Complications and pain did not differ between groups, except for greater stiffness in the last. It emerged that, after initial reduction, specialized treatment could be within 14 days without negative consequences.

According to other authors [23, 34], when external fixation is required, it should be implemented rapidly. Giannicola et al. [17] identified certain factors for poor prognosis: obesity, poor treatment adherence, soft-tissue lesions, and lack of surgeon experience.

Antoni [35] recently analyzed the contribution of anterior capsule bone suture onto the tip of the coronoid process, and found no clinical or radiographic benefit.

### **To sum up:**

- At end of surgery, the elbow should be stable, to allow rapid mobilization to avoid stiffening.
- After initial reduction, specialized treatment is recommended, to optimize results and avoid revision procedures.
- Osteoarthritic remodeling is usual in the medium and long term.

## **7. Conclusion**

- Terrible triad of the elbow is a particular form of fracture-dislocation associating severe bone and soft-tissue lesions jeopardizing elbow stability.
- Management is now well codified:
  - o Emergency reduction.
  - o Specialized surgery, imperatively including lateral compartment reconstruction associating radial head reconstruction by internal fixation or

arthroplasty and lateral repair. The coronoid process should be systematically fixed in type-3 fracture and considered on a case-by-case basis in types 1 and 2. Medial repair and external fixation are indicated only if instability persists after all repair procedures.

## **Acknowledgments**

The authors thank Dr Cécile Nérot for advice and attentive re-editing.

**Disclosure of interest:** The authors have no conflicts of interest to disclose in relation to the present review

**Funding:** none

**Author contributions:**

Xavier Ohl: literature analysis, article writing.

Renaud Siboni: data collection, article re-editing.

## Figure legends

Figure 1: Elbow dislocation mechanisms. From Mansat P, Bonneville N. Luxations du coude. EMC (Elsevier Masson SAS Paris), Appareil Locomoteur, 14-042-A-10, 2009.

axial compression / supination / valgus

Figure 2: Lateral approach showing muscle fascia tear

Figure 3: Lateral approach showing “bare” lateral epicondyle (star) due to complete detachment of the LCL

Figure 4: Lateral approach showing internal fixation of the radial head (RH) by screw and temporary K-wire stabilization

Figure 5: Position of safe zone at radial head: ideal site for fixation screws or plate. © Carole Lafumat

Figure 6: The two main coronoid process fracture classifications: O’Driscoll (left), Regan-Morrey (right). © Carole Lafumat

Figures 7A and 7B: Radioscopy of coronoid process fixation on anterior approach using 2 screws, associate to radial head fixation by 2 screws and lateral ligament repair by anchor on the lateral epicondyle

Figure 8: Lateral approach, with 2 metal anchors on the lateral epicondyle

Figure 9: Lateral approach, showing final aspect of lateral ligament repair using anchors. Annular ligament not yet repaired (located by a suture)

Figure 10: Elbow TT decision tree

Figure 11A: Right elbow TT in a 45 year-old patient, following a fall from a bicycle. Radiograph before reduction

Figure 11B: Sagittal CT reconstruction after emergency reduction. Grade II coronoid fracture and radial head comminution

Figure 11C: Postoperative radiographs after retrograde fixation of coronoid process, fixed radial head prosthesis and lateral repair of LCL

Figures 11D and 11E: Clinical check-up at 3 years, showing slight pronation deficit (compensated for by shoulder abduction) and 30° supination deficit

Figures 11F and 11G: Clinical check-up at 3 years, showing complete flexion and 10° extension deficit

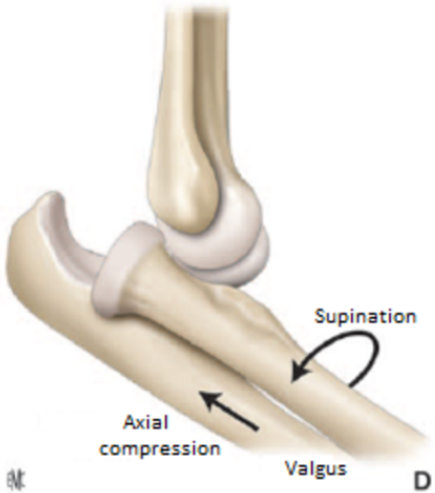
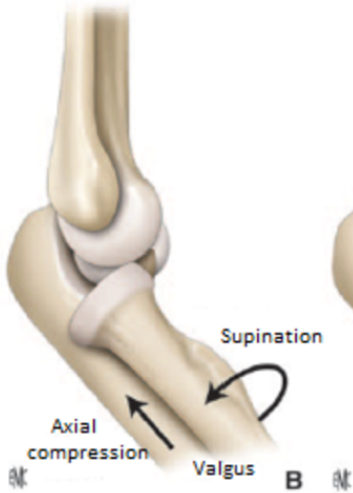
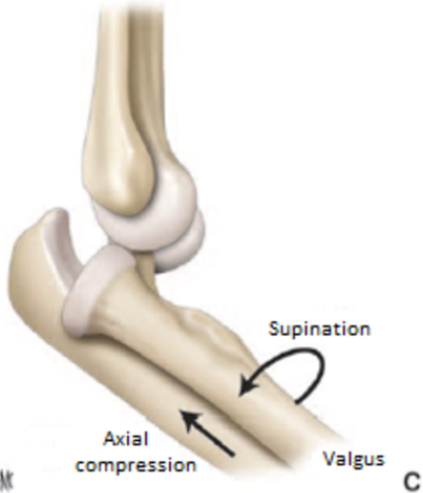
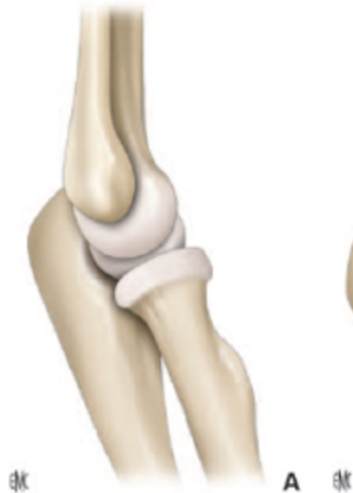## References

1. Sanchez-Sotelo J and Morrey M. Complex elbow instability: surgical management of elbow fracture dislocations. *EFORT Open Rev* 2016;1:183-190.
2. O'Driscoll SW, Morrey BF, Korinek S and An KN. Elbow subluxation and dislocation. A spectrum of instability. *Clin Orthop Relat Res* 1992;Jul:186-97
3. Najd Mazhar F, Jafari D and Mirzaei A. Evaluation of functional outcome after nonsurgical management of terrible triad injuries of the elbow. *J Shoulder Elbow Surg* 2017;26:1342-1347.
4. Bonnevalle N. Radial head replacement in adults with recent fractures. *Orthopaedics & Traumatology: Surgery & Research* 2016;102:S69-S79
5. Chanlalit C, Shukla DR, Fitzsimmons JS, An KN and O'Driscoll SW. The biomechanical effect of prosthetic design on radiocapitellar stability in a terrible triad model. *J Orthop Trauma* 2012;26:539-44.
6. Allavena C, Delclaux S, Bonnevalle N, Rongières M, Bonnevalle P and Mansat P. Outcomes of bipolar radial head prosthesis to treat complex radial head fractures in 22 patients with a mean follow-up of 50 months. *Orthopaedics & Traumatology: Surgery & Research* 2014;100:703-709
7. Chen H, Shao Y and Li S. Replacement or repair of terrible triad of the elbow: A systematic review and meta-analysis. *Medicine (Baltimore)* 2019;98:e13054
8. Kyriacou S, Gupta Y, Bains HK and Singh HP. Radial head replacement versus reconstruction for the treatment of the terrible triad injury of the elbow: a systematic review and meta-analysis. *Arch Orthop Trauma Surg* 2019;139:507-517.
9. Sun H, Duan J and Li F. Comparison between radial head arthroplasty and open reduction and internal fixation in patients with radial head fractures (modified Mason type III and IV): a meta-analysis. *Eur J Orthop Surg Traumatol* 2016;26:283-91.
10. Regan W and Morrey B. Fractures of the coronoid process of the ulna. *J Bone Joint Surg Am* 1989;71:1348-54.
11. O'Driscoll SW, Jupiter JB, Cohen MS, Ring D and McKee MD. Difficult elbow fractures: pearls and pitfalls. *Instr Course Lect* 2003;52:113-34.
12. Jeon IH, Sanchez-Sotelo J, Zhao K, An KN and Morrey BM. The contribution of the coronoid and radial head to the stability of the elbow. *J Bone Joint Surg Br* 2012;94:86-92.
13. Lor KKH, Toon DH and Wee ATH. Buttress plate fixation of coronoid process fractures via a medial approach. *Chin J Traumatol* 2019;22:255-260.
14. Reichel LM, Milam GS and Reitman CA. Anterior approach for operative fixation of coronoid fractures in complex elbow instability. *Tech Hand Up Extrem Surg* 2012;16:98-104.
15. Yang X, Chang W, Chen W, Liu S, Zhu Y and Zhang Y. A novel anterior approach for the fixation of ulnar coronoid process fractures. *Orthop Traumatol Surg Res* 2017;103:899-904.
16. Dyer G and Ring D. Terrible Triad Fracture-Dislocations of the Elbow. *Operative Techniques in Orthopaedics* 2013;23:198-204.
17. Giannicola G, Calella P, Piccioli A, Scacchi M and Gumina S. Terrible triad of the elbow: is it still a troublesome injury? *Injury* 2015;46 Suppl 8:S68-76


18. Papatheodorou LK, Rubright JH, Heim KA, Weiser RW and Sotereanos DG. Terrible triad injuries of the elbow: does the coronoid always need to be fixed? *Clin Orthop Relat Res* 2014;472:2084-91
19. McGuire D and Bain GI. Medial and Lateral Collateral Ligament Repair or Reconstruction of the Elbow. *Operative Techniques in Orthopaedics* 2013;23:205-214
20. Chemama B, Bonneville N, Peter O, Mansat P and Bonneville P. Terrible triade du coude : description et prise en charge. *Revue de Chirurgie Orthopédique et Traumatologique* 2010;96:191-198
21. Zhou C, Xu J, Lin J, Lin R, Chen K, Kong J et al. Comparison of a single approach versus double approaches for the treatment of terrible triad of elbow—A retrospective study. *International Journal of Surgery* 2018;51:49-55.
22. Duparc F and Merlet M-C. Prevention and management of early treatment failures in elbow injuries. *Orthopaedics & Traumatology: Surgery & Research* 2019;105:S75-S87.
23. Iordens GIT, Den Hartog D, Van Lieshout EMM, Tuinebreijer WE, De Haan J, Patka P et al. Good functional recovery of complex elbow dislocations treated with hinged external fixation: a multicenter prospective study. *Clinical Orthopaedics and Related Research* 2015;473:1451-1461.
24. Egol KA, Immerman I, Paksima N, Tejwani N and Koval KJ. Fracture-dislocation of the elbow functional outcome following treatment with a standardized protocol. *Bull NYU Hosp Jt Dis* 2007;65:263-70
25. Pugh DM, Wild LM, Schemitsch EH, King GJ and McKee MD. Standard surgical protocol to treat elbow dislocations with radial head and coronoid fractures. *J Bone Joint Surg Am* 2004;86:1122-30.
26. Ring D, Jupiter JB and Zilberfarb J. Posterior dislocation of the elbow with fractures of the radial head and coronoid. *J Bone Joint Surg Am* 2002;84:547-51
27. Winter M, Chuinard C, Cikes A, Pelegri C, Bronsard N and de Peretti F. Surgical management of elbow dislocation associated with non-reparable fractures of the radial head. *Chir Main* 2009;28:158-67.
28. Chen HW, Liu GD and Wu LJ. Complications of treating terrible triad injury of the elbow: a systematic review. *PLoS One* 2014;9:e97476.
29. Forthman C, Henket M and Ring DC. Elbow Dislocation With Intra-Articular Fracture: The Results of Operative Treatment Without Repair of the Medial Collateral Ligament. *The Journal of Hand Surgery* 2007;32:1200-1209.
30. Garrigues GE, Wray WH, 3rd, Lindenhovius AL, Ring DC and Ruch DS. Fixation of the coronoid process in elbow fracture-dislocations. *J Bone Joint Surg Am* 2011;93:1873-81.
31. Kani KK and Chew FS. Terrible triad injuries of the elbow. *Emerg Radiol* 2019;26:341-347.
32. Zaidenberg EE, Abrego MO, Donndorff AG, Boretto JG, De Carli P and Gallucci GL. Treatment of terrible triad injuries at a mean follow-up of nine years. *Shoulder Elbow* 2019;11:450-458.
33. Zhou C, Lin J, Xu J, Lin R, Chen K, Sun S et al. Does Timing of Surgery Affect Treatment of the Terrible Triad of the Elbow? *Med Sci Monit* 2018;24:4745-4752.
34. Sorensen AK and Sojbjerg JO. Treatment of persistent instability after posterior fracture-dislocation of the elbow: restoring stability and mobility by internal fixation and hinged external fixation. *J Shoulder Elbow Surg* 2011;20:1300-9.

35. Antoni M, Eichler D, Kempf JF and Clavert P. Anterior capsule re-attachment in terrible triad elbow injury with coronoid tip fracture. *Orthop Traumatol Surg Res* 2019;105:1575-1583.

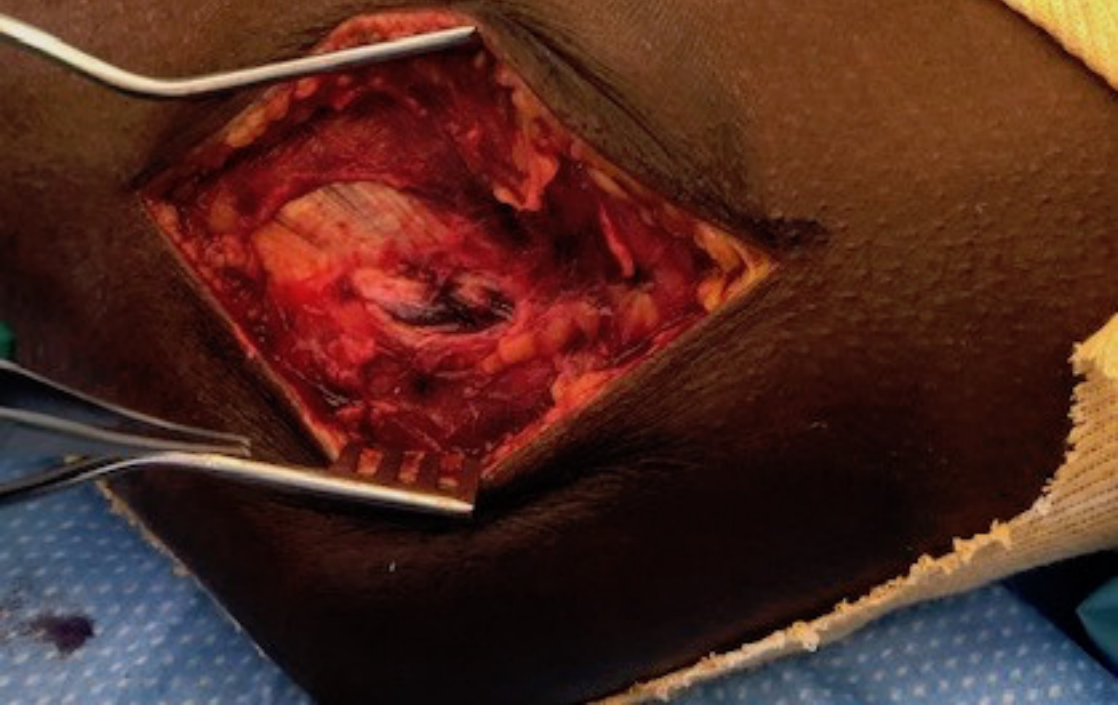




**Anterior**



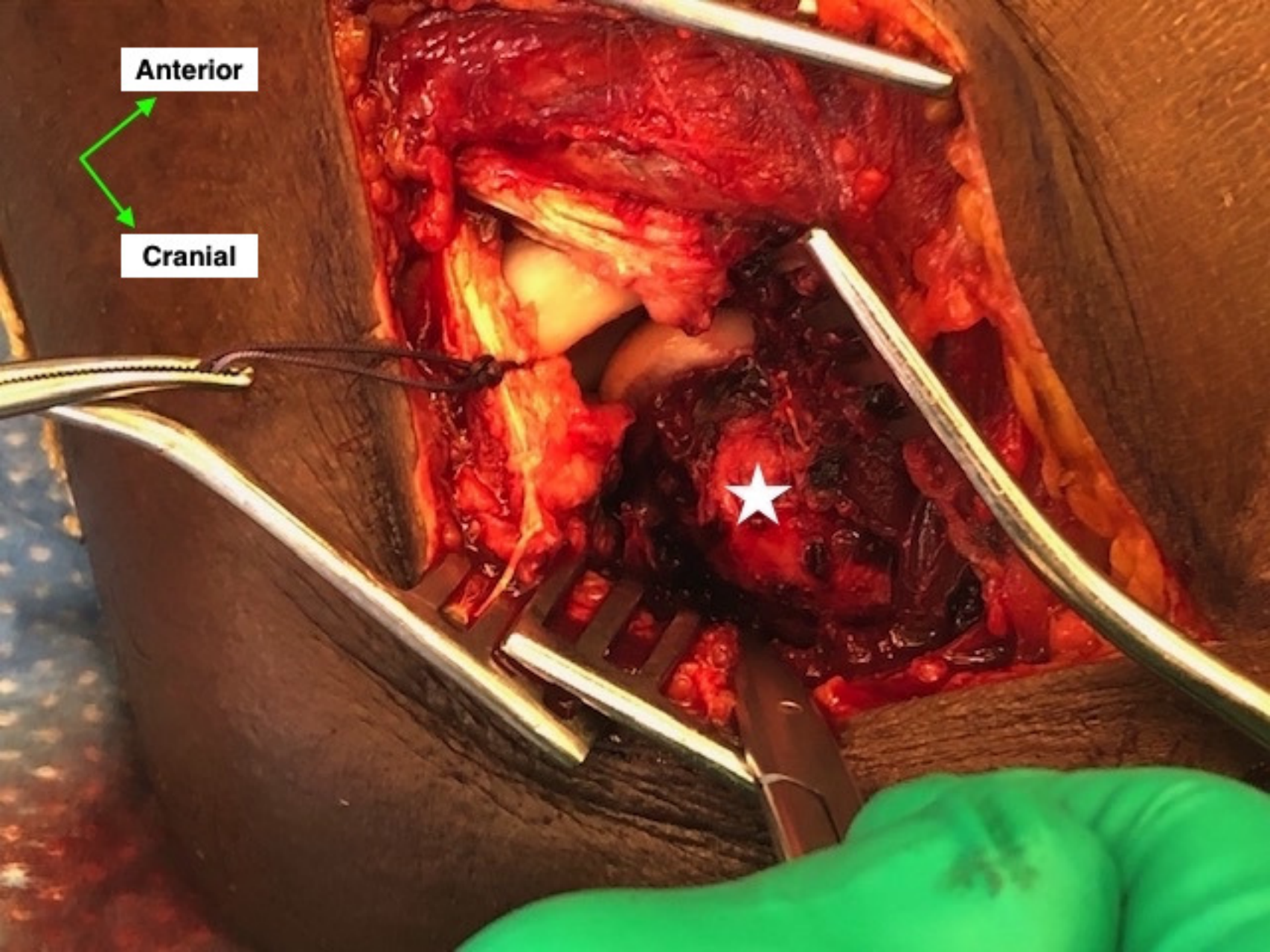
**Cranial**



**Anterior**



**Cranial**



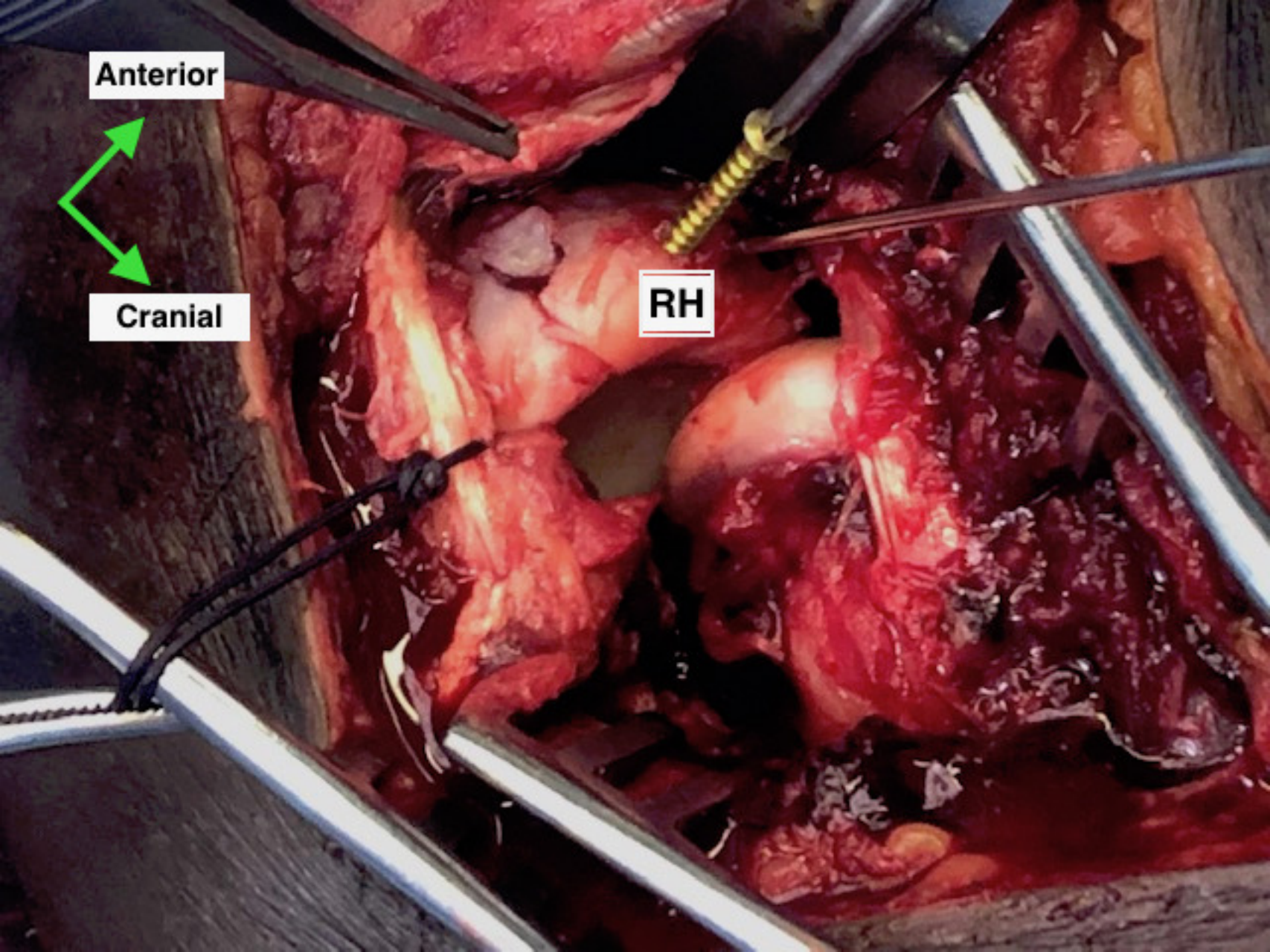


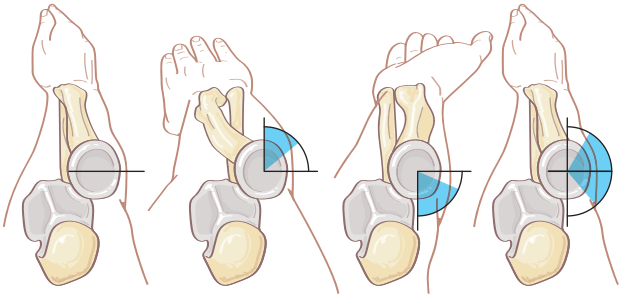
**Anterior**

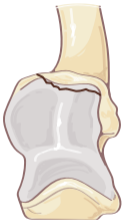

**Cranial**

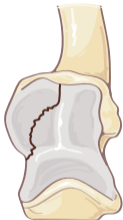**RH**



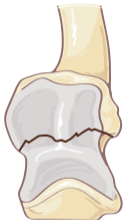



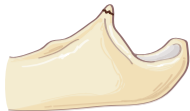Type 1



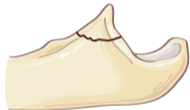Type 2



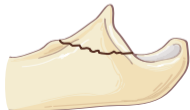Type 3



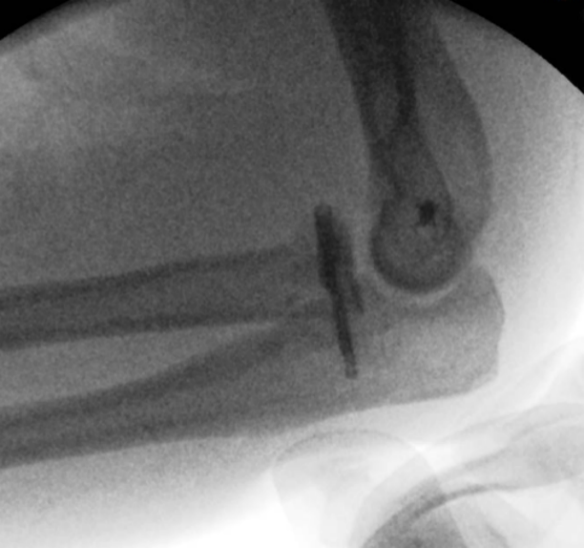Type 1

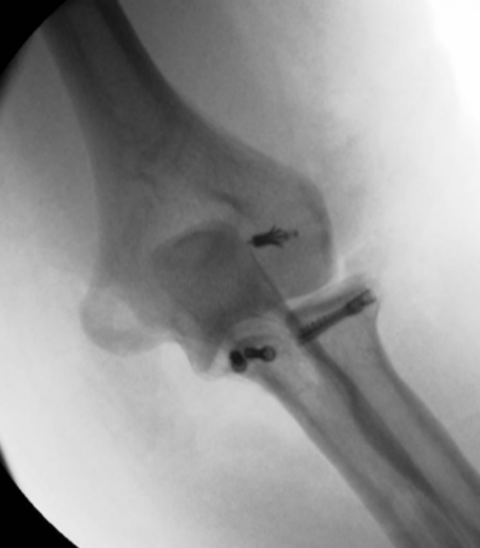

Type 2



Type 3



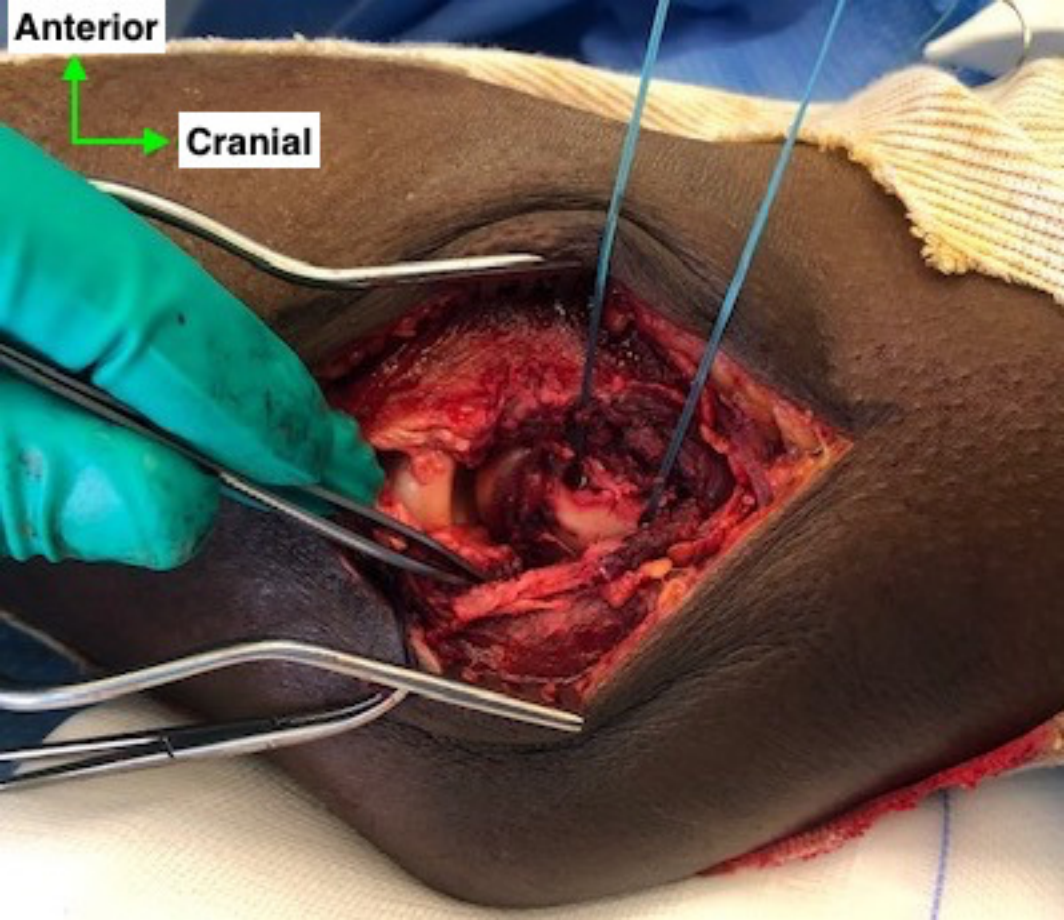




**Anterior**

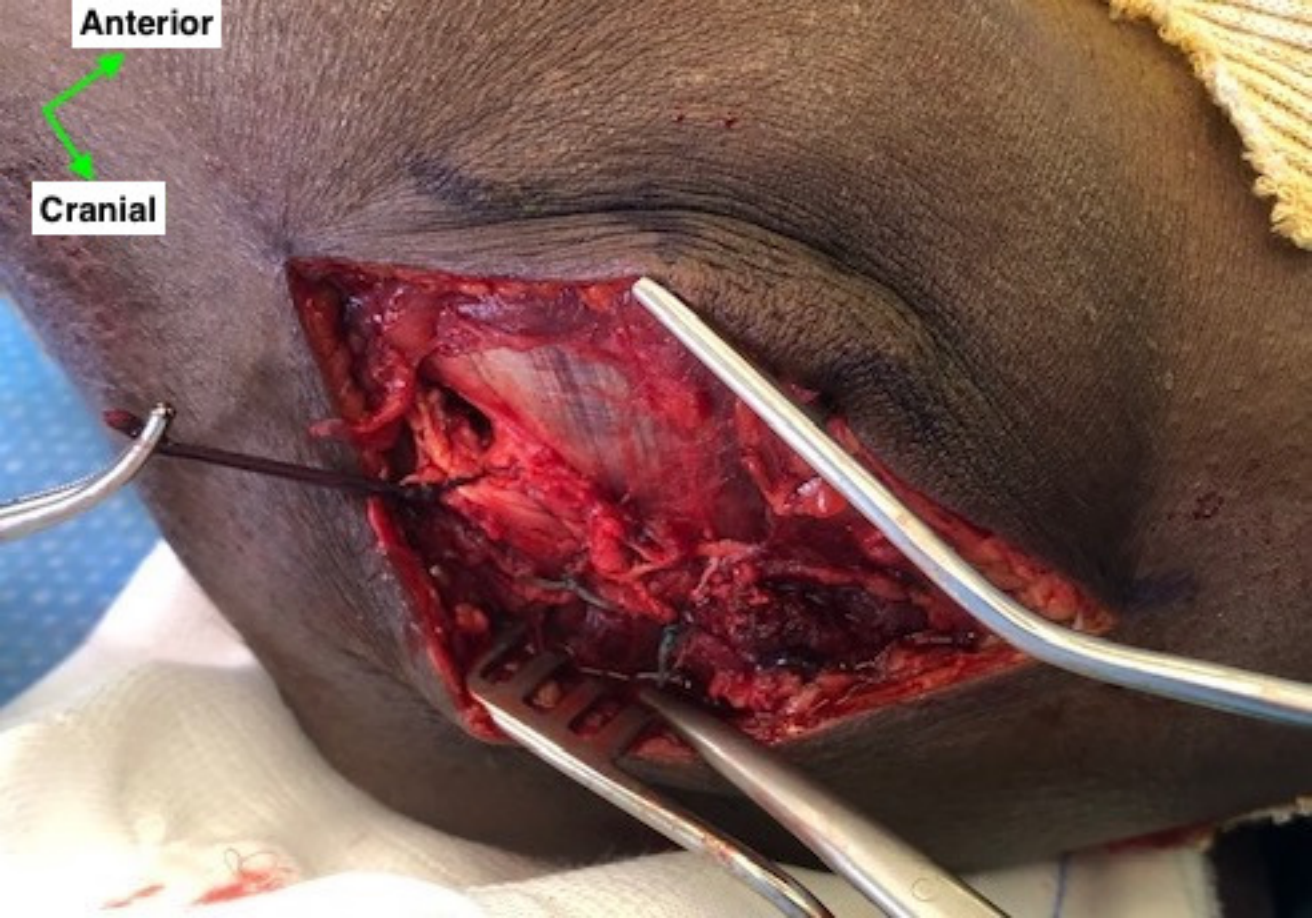


**Cranial**



**Anterior**

**Cranial**



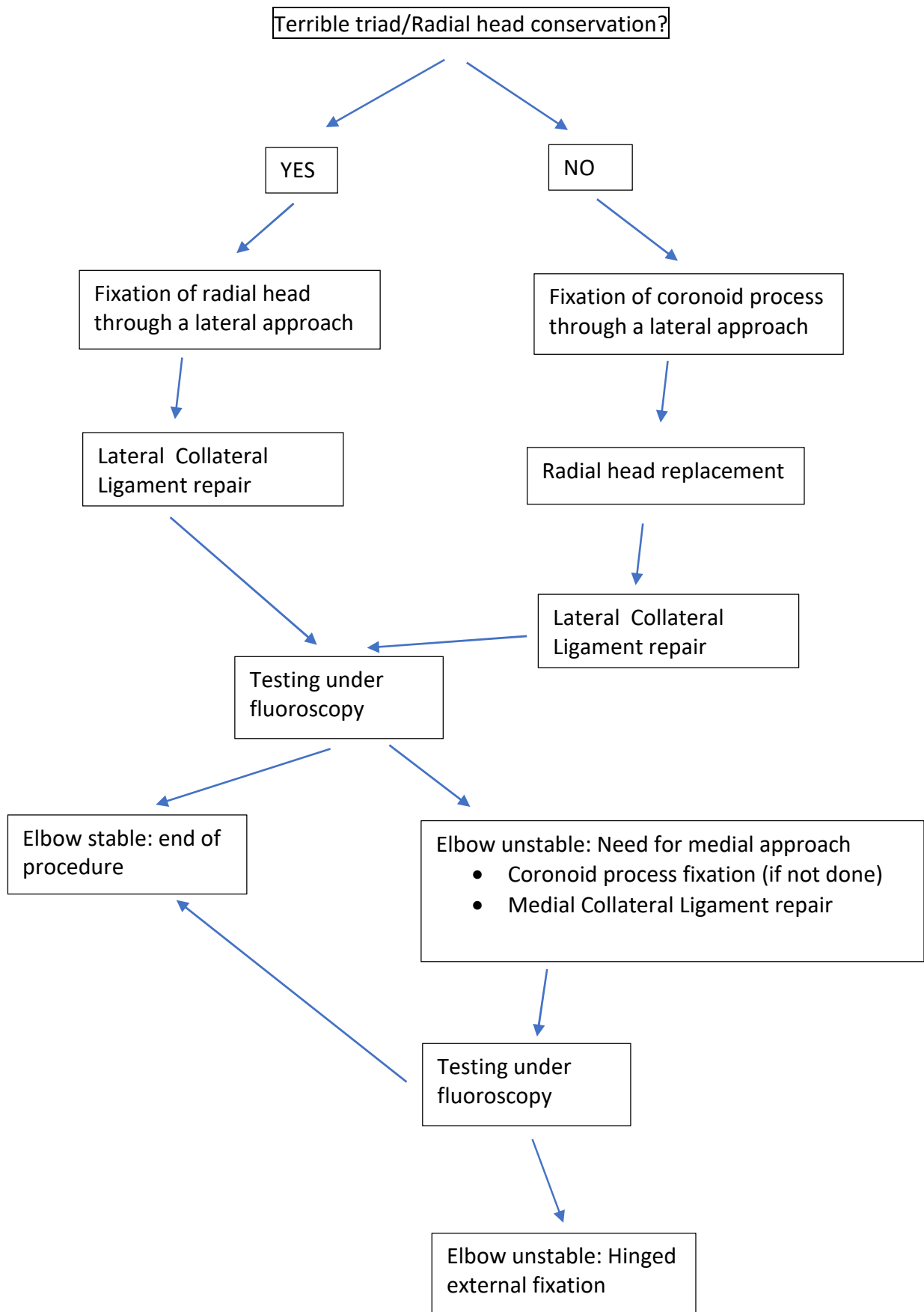
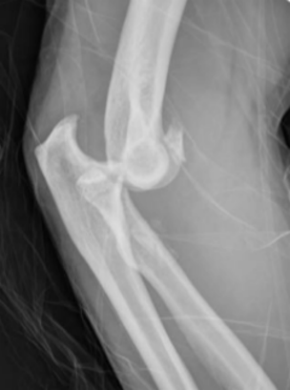
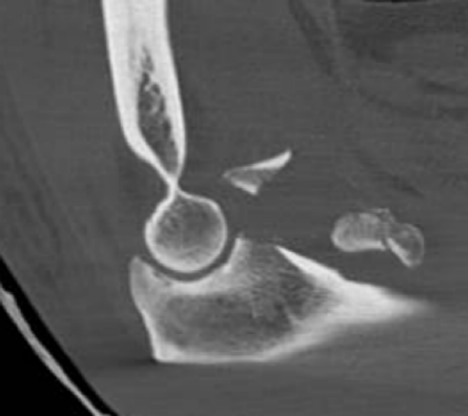
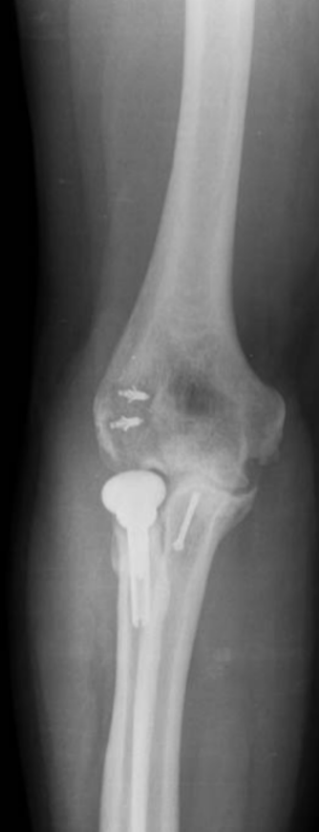Figure 10:





D



D











