



**HAL**  
open science

## First use of a new rapid multiplex PCR system for the microbiological diagnosis and the clinical management of severe infectious keratitis: A case report

Thomas Ferreira de Moura, Anne Limelette, Carl Arndt, Thomas Guillard,  
Laurent Andreoletti, Alexandre Denoyer

### ► To cite this version:

Thomas Ferreira de Moura, Anne Limelette, Carl Arndt, Thomas Guillard, Laurent Andreoletti, et al.. First use of a new rapid multiplex PCR system for the microbiological diagnosis and the clinical management of severe infectious keratitis: A case report. *American Journal of Ophthalmology Case Reports*, 2022, 27, pp.101601. 10.1016/j.ajoc.2022.101601 . hal-03693104

**HAL Id: hal-03693104**

**<https://hal.univ-reims.fr/hal-03693104>**


Submitted on 10 Jun 2022

**HAL** is a multi-disciplinary open access archive for the deposit and dissemination of scientific research documents, whether they are published or not. The documents may come from teaching and research institutions in France or abroad, or from public or private research centers.

L'archive ouverte pluridisciplinaire **HAL**, est destinée au dépôt et à la diffusion de documents scientifiques de niveau recherche, publiés ou non, émanant des établissements d'enseignement et de recherche français ou étrangers, des laboratoires publics ou privés.



Distributed under a Creative Commons Attribution - NonCommercial - NoDerivatives 4.0 International License



## First use of a new rapid multiplex PCR system for the microbiological diagnosis and the clinical management of severe infectious keratitis: A case report

Thomas Ferreira de Moura<sup>a,b</sup>, Anne Limelette<sup>c</sup>, Carl Arndt<sup>a</sup>, Thomas Guillard<sup>c,d</sup>,  
Laurent Andreoletti<sup>b,c,1</sup>, Alexandre Denoyer<sup>a,b,\*,1</sup>

<sup>a</sup> University of Reims Champagne-Ardenne, University Hospital, Ophthalmology, Reims, France

<sup>b</sup> University of Reims Champagne-Ardenne, Research Team EA4684, CARDIOVIR, Reims, France

<sup>c</sup> University Hospital, Department of Biology, Reims, France

<sup>d</sup> University of Reims Champagne-Ardenne, Inserm UMRS1250, P3Cell, Reims, France

### ARTICLE INFO

#### Keywords:

Fortified antibiotic  
Cornea  
Infectious keratitis  
Rapid multiplex system

### ABSTRACT: ( 2 0 6 W O R D S )

**Purpose:** We report the use of a rapid multiplex polymerase chain reaction (PCR) system in the microbiological diagnosis and the therapeutic management of a severe bacterial keratitis case.

**Observations:** During the management of a severe bacterial keratitis case, standard microbiological diagnostic methods were performed. At the same time, an additional ocular swab sampling from the cornea was performed and analyzed using two rapid multiplex PCR assays allowing the simultaneous detection of 29 different virus, yeast and bacteria genomes. Using combination of two rapid multiplex PCR systems, the microbiological diagnosis of a severe *Pseudomonas aeruginosa* induced keratitis was performed within 90 minutes after an ocular sampling. A rapid subsequent adaptation of local antibiotic treatment was performed allowing to the young patient to regain 6 months after her hospital admission a final visual acuity of 20/20 in her right eye.

**Conclusions and importance:** The present case report suggests that the use of a rapid multiplex PCR strategy may result in a decrease of the mean hospital stage duration for severe infectious keratitis and in an improvement of the clinical outcome of severe keratitis infections. Nevertheless, additional prospective studies are needed to evaluate whether this innovative strategy may replace the current standard approach and optimize the therapeutic management of severe corneal infections.

### 1. Introduction

Herein, we report a severe infectious keratitis case in a young immunocompetent woman where the use of rapid multiplex RT-PCR systems to detect the causal pathogen in corneal infection allowed improving the clinical management of a bacterial corneal infection with severity criteria.<sup>1</sup>

### 2. Case report

In June 2019, a 20-year-old immunocompetent female patient presented to the ophthalmologic department of the University Hospital of Reims for a pain in the right eye associated with a decrease in visual

acuity. The patient had no previous ophthalmological history except for myopia corrected by orthokeratology. The visual acuity of the right eye was measured at counting fingers (CF) at 1 m that of the left eye was at 20/20.

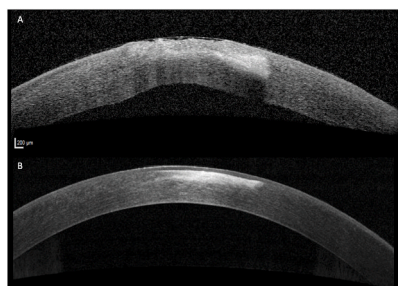
Biomicroscopic examination of the right eye revealed a central corneal ulcer 2.2 mm in diameter associated with stromal edema and folds of Descemet's membrane (Fig. 1). A homolateral cellular tyndall effect was assessed at 1+/4+. There was no hypopyon, radial kerato-neuritis or satellite infiltrates. Biomicroscopic examination of the anterior segment of the left eye was unremarkable.

In view of this clinical presentation, the diagnosis of microbial keratitis of the right eye was evident and the severity of the infection was established following the "1,2,3" rule.<sup>1</sup> By consequent, the patient was

\* Corresponding author. Department of ophthalmology, Robert Debré University Hospital, rue du general Koenig, 51100, Reims, France.

E-mail address: [alexandre.denoyer@gmail.com](mailto:alexandre.denoyer@gmail.com) (A. Denoyer).

<sup>1</sup> Laurent Andreoletti and Alexandre Denoyer equally contributed in drafting the report as last co-authors.



**Fig. 1. A:** OCT image of the cornea of the right eye at initial management. Corneal infection resulted in stromal edema, and corneal epithelial defects together with tissue necrosis. **B:** OCT image of the cornea of the right eye at 6 months, showing complete re-epithelialization and anterior stromal fibrosis.

hospitalized in our department. Corneal scraping by spatula and swabbing (eSwab®) of the infected ocular area were performed in order to carry out referenced diagnostic methods (direct microscopic examination with Gram stain, bacterial and fungal cultures, viral and amoebic polymerase chain reaction [PCR]).<sup>2</sup>

Because of the absence of international consensus concerning the management of bacterial corneal ulcer with severity criteria and following French recommendations,<sup>3</sup> a local fortified antibiotic therapy with ticarcillin/amikacin/vancomycin was started at a rate of one

drop/hour day and night upon admission of the patient to our department. Voriconazole, PHMB (polyhexamethylene biguanide) and hexamidine were started at the same frequency, because of the diversity of pathogens may be involved in orthokeratology lenses-related corneal ulcer.

The direct examination by Gram coloration was not informative. In a delay of 1 h and a half after the cornea sampling, rapid multiplex PCR assays detected the presence of significant levels of *Pseudomonas aeruginosa* without any antibiotic gene resistance molecular detection (Fig. 2). By consequences, the conventional empiric antibiotherapy was stopped and a combination of ciprofloxacin and amikacin (one drop an hour) has been conducted for 2 days according to the bacteria found by PCR. Frequency of eye drop delivery has been progressively decreased, according to the daily clinical follow-up, and the treatment was tapered off four weeks after the diagnosis.

After five days, the conventional bacterial culture revealed the presence of *Corynebacterium tuberculostearicum*, a skin commensal bacterium usually found on the eyelid. The prolonged fungal culture (one-week incubation time) was also negative as the amoebic PCR assay. *Pseudomonas aeruginosa* was not detected following conventional bacteriological culture assays.

During the clinical follow-up of the patient, the visual acuity of the right eye improved significantly from 20/40 at the first month to 20/25 at 3 months, and finally stabilized at 20/20 6 months and one year after the diagnosis.

Results Summary – Interpretation BCID Panel			
Antimicrobial Resistance Genes		Yeast	
Not Detected	KPC (carbapenem-resistance gene)	Not Detected	Candida albicans
Not Detected	mecA (methicillin-resistance gene)	Not Detected	Candida glabrata
Not Detected	vanA/B (vancomycin-resistance genes)	Not Detected	Candida krusei
Gram Positive Bacteria		Not Detected	Candida parapsilosis
Not Detected	Enterococcus	Not Detected	Candida tropicalis
Not Detected	Listeria monocytogenes		
Not Detected	Staphylococcus aureus		
Not Detected	Streptococcus agalactiae (Group B)		
Not Detected	Streptococcus pneumoniae		
Not Detected	Streptococcus pyogenes (Group A)		
Gram Negative Bacteria			
Not Detected	Acinetobacter baumannii		
Not Detected	Enterobacter cloacae complex		
Not Detected	Escherichia coli		
Not Detected	Klebsiella oxytoca		
Not Detected	Klebsiella pneumoniae		
Not Detected	Proteus		
Not Detected	Serratia marcescens		
Not Detected	Haemophilus influenzae		
Not Detected	Neisseria meningitidis		
<b>Detected</b>	<b>Pseudomonas aeruginosa</b>		

Results Summary – Interpretation Meningitis/Encephalitis (ME) Panel			
Bacteria		Viruses	
Not Detected	Escherichia coli K1	Not Detected	Cytomegalovirus
Not Detected	Haemophilus influenzae	Not Detected	Enterovirus
Not Detected	Listeria monocytogenes	Not Detected	Herpes simplex virus 1
Not Detected	Neisseria meningitidis	Not Detected	Herpes simplex virus 2
Not Detected	Streptococcus agalactiae	Not Detected	Herpes simplex virus 6
Not Detected	Streptococcus pneumoniae	Not Detected	Human parechovirus
Yeast		Not Detected	Varicella zoster virus
Not Detected	Cryptococcus neoformans/gattii		

**Fig. 2.** Pathogens and antimicrobial resistance markers tested by our FilmArray® strategy combining the two commercially available Meningitis-Encephalitis (ME) and Blood Culture Identification (BCID) panels.

### 3. Discussion

Microbial keratitis is a severe and often blindness-inducing disease that represents today the first reason for extended hospitalization (more than 5 days) in ophthalmology.<sup>4</sup> The diagnosis relies on clinical examination and leads to immediate hospitalization in the presence of severity criteria.<sup>5</sup> Among bacterial etiologies, 3 groups of microbial agents predominate, including *Staphylococci*, *Streptococci*, and *Pseudomonas*.<sup>6</sup>

The prognosis depends on both the extent and topography of the initial lesion and on a rapid treatment. As a result, the more the treatment is started quickly and efficiently, the better are the outcomes.<sup>7</sup> Therefore, the time delay of microbiological investigations resulting in the identification of etiological pathogens (bacterial, viral, fungal or parasitic) remains a determinant factor driving a targeted anti-microbiological treatment and impacting the visual prognosis as well as the mean duration time of hospitalization.<sup>8</sup>

Today the gold-standard for microbiological diagnosis according to the recommendations of scientific societies is based on direct Gram examination, standard bacterial cultures associated with the detection of HSV1; HSV 2 and VZV,<sup>2</sup> enteroviruses and adenoviruses by PCR assays performed on DNA/RNA extracts of corneal samples (corneal scrapings) taken at the time of the first visit. Classical bacterial positive results are followed by standard phenotypic tests allowing to identify sensitivity or resistance to antibiotics. The global microbiological diagnosis process requires several days before etiological confirmation and therefore delays the initiation of a targeted anti-microbial therapy. According to *Yeh DL and al.* of 307 cases of microbial keratitis collected, culture is positive in only 68% of cases.<sup>9</sup> Several factors could explain the low sensitivity of microbial cultures in the etiological diagnosis of infectious keratitis. First of all, the difficulty of accurately sampling this tissue due to pain and photophobia. In addition, the infectious area is not only composed of pathogens but also of immune cells and many cellular degradation products as well as pathogen's DNA and RNA, which can't be detected by conventional diagnostics methods. We hypothesize that nucleic acid detection of pathogens would therefore be more sensitive than conventional methods in the microbiological diagnosis of severe infectious keratitis, a good example of which is the present case.

Recently, rapid multiplex PCR systems were developed for detecting 18 to 27 pathogens (bacterial, viral, parasitic and fungal) in 75 minutes. These rapid PCR systems have been developed initially for the detection of the main prevalent infectious agents responsible for severe sepsis (FilmArray® BICD kit)<sup>10</sup> and meningoencephalitis ("ME" kit, FilmArray®).<sup>11,12</sup> The FilmArray® system is an automated in vitro diagnostic (IVD) device for the detection of bacterial, viral, parasitic or fungal DNA or RNA in clinical samples. The general principle is based on a nested multiplex PCR (NM-PCR) assay, itself composed of 2 distinct phases. During the first phase, so-called external primers are used to perform a multiplex PCR on the sequences of interest present in the clinical sample. Secondly, a new PCR will amplify in a simplex manner the sequences previously amplified in the first PCR. The resulting PCR products are then automatically evaluated by melting curve analysis to specifically identify pathogen genomes. This platform is also able to determine for the presence of antibiotic resistance genes such as *vanA/B*, *mecA* or *KPC* (Fig. 2). To date, 4 panels exist: Respiratory, BCID, gastrointestinal (GI) and ME. The benefits of rapid PCR multiplex system in time of therapeutic adjustment and diagnostic capacities have been demonstrated by several authors. Thus, *Vincent and al*<sup>12</sup> estimated that the sensitivity, specificity, positive predictive value and negative predictive value of the ME panel were respectively 94.2%, 98.2%, 84.3% and 99.4%, for the microbiological diagnosis of meningoencephalitis, indicating that FilmArray® ME was an efficient and rapid tool with a higher sensitivity than conventional diagnostic methods. The increase of this sensitivity would be useful in ophthalmology due to the localization of the injured area to be sampled and the ocular pain that makes sampling relatively difficult. Moreover, it has been demonstrated that the use of FilmArray®

BCID in patients hospitalized in intensive care for septic shock, allows a modification of the first line antimicrobial treatment towards a treatment targeting the detected pathogen in 32% of patients<sup>13</sup> and to reduce the time of identification of the pathogen by an average of 1.1 day (0.82 days vs. 1.92 days;  $p < 0.0001$ ) compared to conventional microbiological diagnostic methods.<sup>14</sup> In addition, the use of FilmArray® BCID enabled rapid implementation of additional multidrug-resistant infection prevention and control practices in 14% of patients in the study.<sup>13</sup>

Several applications of multiplex PCR in ophthalmology were reported in literature, but they were able to identify only a few bacteria strains and no gens resistance<sup>15</sup> whereas the infection's prognosis is directly correlated to the pathogen involved. Our PCR procedure may not replace the culture methods, and it would be important to perform both cultures and PCR to increase the sensitivity for the etiological diagnosis of infectious keratitis.

We are also aware that the multiplex PCR platform we presented could be expensive, but this novel technique may participate to decrease time delay hospitalization which constitute an important part of health care system' expenditures.

Finally, this first use of FilmArray® in ophthalmology seems to be hopeful but a larger case series demonstrating diagnostic utility or analytical studies are needed to assess this possibility. In the future, it would be interesting to develop a specific panel of pathogens mostly encountered in severe infectious keratitis also. One may suggest such a panel would include *Fusarium*, *Aspergillus*, *Acanthamoeba* for the yeast and parasites, HSV/VZV for the viruses, and *Pseudomonas*, *Staphylococcus*, *Streptococcus* and *Moraxella* for the bacteria.

### 4. Conclusion

Despite its diagnostic capabilities, its simplicity of use, the current emergence of multidrug-resistant bacteria and the current trend reducing hospital beds, multiplex PCR array platform has unfortunately never been used in the field of ophthalmology. By adapting the use of infectious agents panels tested by this rapid multiplex PCR system to the most prevalent pathogens responsible for severe infectious keratitis, the daily use of a such diagnostic platform in the management of severe microbial keratitis might allow a more rapid adaptation of targeted antibiotic/antiviral treatments, and a decrease in ocular toxicity induced by inappropriate eye drops.<sup>16</sup> The use of a such rapid multiplex PCR strategy might result in a decrease of the mean hospital stage duration for severe infectious keratitis and might improve the clinical outcome of such a severe ocular disease. Nevertheless, additional prospective studies are needed to evaluate whether this innovative technique may replace the current standard approach and optimize the management of severe corneal infection.

### Patient consent

The patient consented to publication of the case in writing. This report does not contain any personal information that could lead to the identification of the patient.

### Funding

No funding or grant support.

### Authorship

All authors attest that they meet the current ICMJE criteria for Authorship.

### Declaration of competing interest

LA is a scientific consultant for Biomerieux. The other authors have no financial disclosure.

## Acknowledgements

None.

## References

- Vital MC, Bellosso M, Prager TC, Lanier JD. Classifying the severity of corneal ulcers by using the "1, 2, 3" rule. *Cornea*. 2007;26(1):16–20.
- Kaneko H, Higaki S, Fukuda M, et al. The quantitative detection of herpes simplex virus, varicella zoster virus, an cytomegalovirus DNAs in recipient corneal buttons. *Cornea*. 2010;29:1436–1439.
- Bourcier T, Chaumeil C, Borderie V, et al. Kératites bactériennes. In: *Surface oculaire. Rapport annuel de la société française d'ophtalmologie*. Elsevier Masson; 2015: p265–274.
- Bourcier T. *Kératites bactériennes*. EMC. 2007;10.
- Vital MC, Bellosso M, Prager TC, Lanier JD. Classifying the severity of corneal ulcers by using the "1, 2, 3" rule. *Cornea*. 2007;26:16–20.
- Ting DSJ, Ho CS, Cairns J, et al. 12-year analysis of incidence, microbiological profiles and in vitro antimicrobial susceptibility of infectious keratitis: the Nottingham Infectious Keratitis Study. *Br J Ophthalmol*. 2021;105(3):328–333.
- Kerautret J, Raobela L, Colin J. Serious bacterial keratitis: a retrospective clinical and microbiological study. *J Fr Ophthalmol*. 2006;29:883–888.
- Oldenburg CE, Lietman TM. The challenge of controlling infectious keratitis. *Am J Ophthalmol*. 2017;176. editorial(xv-xvi).
- Yeh DL, Stinnett SS, Afshari NA. Analysis of bacterial cultures in infectious keratitis, 1997 to 2004. *Am J Ophthalmol*. 2006;142:1066–1068.
- Rule R, Paruk F, Becker P, Neuhoff M, Chausse J, Said M. Clinical utility of the BioFire FilmArray Blood Culture Identification panel in the adjustment of empiric antimicrobial therapy in the critically ill septic patient. *PLoS One*. 2021;16(7), e0254389.
- FDA Allows Marketing of the First Nucleic Acid-Based Test to Detect Multiple Pathogens from a Single Sample of Cerebrospinal Fluid. FDA press release; 2015.
- Vincent JJ, Zandotti C, Baron S, et al. Point-of-care multiplexed diagnosis of meningitis using the FilmArray® ME panel technology. *Eur J Clin Microbiol Infect Dis*. 2020;39(8):1573–1580.
- Rule R, Paruk F, Becker P, Neuhoff M, Chausse J, Said M. Clinical utility of the BioFire FilmArray Blood Culture Identification panel in the adjustment of empiric antimicrobial therapy in the critically ill septic patient. *PLoS One*. 2021;16(7), e0254389.
- Messacar K, Hamilton SL, Prinzi AM. Rapid Identification of nonblood sterile site broth cultures using the FilmArray blood culture identification panel. *Diagn Microbiol Infect Dis*. 2019;93(1):22.
- Nakano S, Sugita S, Tomaru Y. Establishment of multiplex solid-phase strip test for detection of 24 ocular infectious disease pathogens. *Investig Ophthalmol Vis Sci*. 2017; 58(3):1553–1559.
- Lin CP, Boehnke M. Effect of fortified antibiotic solutions on corneal epithelial wound healing. *Cornea*. 2000;19(2):204–206.