



Meniscal Ramp Repair: A 2-Portal Posteromedial Approach

Renaud Siboni, Charles Pioger, Christophe Jacquet, Caroline Mouton, Julie Seil, Cécile Toanen, Romain Seil

► To cite this version:

Renaud Siboni, Charles Pioger, Christophe Jacquet, Caroline Mouton, Julie Seil, et al.. Meniscal Ramp Repair: A 2-Portal Posteromedial Approach. *Arthroscopy Techniques*, 2022, 11 (7), pp.e1163-e1169. 10.1016/j.eats.2022.02.026 . hal-03763961

HAL Id: hal-03763961

<https://hal.univ-reims.fr/hal-03763961>

Submitted on 30 Aug 2022

HAL is a multi-disciplinary open access archive for the deposit and dissemination of scientific research documents, whether they are published or not. The documents may come from teaching and research institutions in France or abroad, or from public or private research centers.

L'archive ouverte pluridisciplinaire **HAL**, est destinée au dépôt et à la diffusion de documents scientifiques de niveau recherche, publiés ou non, émanant des établissements d'enseignement et de recherche français ou étrangers, des laboratoires publics ou privés.



Distributed under a Creative Commons Attribution - NonCommercial - NoDerivatives 4.0 International License

Meniscal Ramp Repair: A 2-Portal Posteromedial Approach



Renaud Siboni, M.D., Charles Pioger, M.D., Christophe Jacquet, M.D.,
Caroline Mouton, Ph.D., Julie Seil, Cécile Toanen, M.D., and Romain Seil, M.D., Ph.D.

Abstract: The management of medial meniscus ramp lesions can be challenging. The current gold standard technique to repair these lesions is the transnotch view combined with a single instrumental posteromedial portal. However, it does not provide direct visualization of the ramp and does not allow for an anatomic repair. In this Technical Note, a new technique is described with 2 posteromedial portals: a posteromedial viewing portal and working portal. This 2-portal approach aims to improve visualization of the lesion and its repair, as well as allow for a technically easier repair.

Ramp lesions are defined as tears of the posterior horn of the medial meniscus (PHMM), in particular, involving its capsular attachments with and injuries to the meniscotibial ligament. On magnetic resonance imaging (MRI), an irregular posterior meniscal outline and perimeniscal fluid signal separating the meniscus and the capsule may indicate a ramp lesion (Fig 1).¹ The sensitivity of MRI to detect ramp lesions is highly debated, however, so arthroscopic exploration remains the gold standard for proper identification of these lesions.

In the anterior cruciate ligament (ACL)-deficient knee, the incidence of ramp lesions has been reported to vary from 16% to 40%.² Many expert centers routinely promote systematic exploration of the posteromedial (PM) compartment to detect and repair these lesions.³ If left untreated, they may indeed compromise

From the Department of Orthopaedic Surgery, Centre Hospitalier Luxembourg – Clinique d'Eich, Luxembourg (R.S., C.P., C.M., J.S., R.S.); the Department of Orthopaedic Surgery, Reims Teaching Hospital, Hôpital Maison Blanche, Reims, France (R.S.); the Department of Orthopaedic Surgery, Ambroise Paré Hospital, Paris Saclay University, Boulogne-Billancourt, France (C.P.); the Department of Orthopaedic Surgery and Traumatology, Institute for Movement and Locomotion, St. Marguerite Hospital, Marseille, France (C.J.); the Luxembourg Institute of Research in Orthopaedics, Sports Medicine and Science, Luxembourg (C.M., R.S.); the Department of Orthopaedic Surgery, Versailles Hospital, 78150, Le Chesnay, France (C.T.); and Human Motion, Orthopaedics, Sports Medicine and Digital Methods, Luxembourg (R.S.).

The authors report that they have no conflicts of interest in the authorship and publication of this article. Full ICMJE author disclosure forms are available for this article online, as [supplementary material](#).

Received January 14, 2022; accepted February 10, 2022.

Address correspondence to Pr Romain Seil, M.D., Ph.D., Department of Orthopaedic Surgery, Centre Hospitalier Luxembourg – Clinique d'Eich, 78 Rue d'Eich L-1460 Luxembourg. E-mail: rseil@yahoo.com

© 2022 THE AUTHORS. Published by Elsevier Inc. on behalf of the Arthroscopy Association of North America. This is an open access article under the CC BY-NC-ND license (<http://creativecommons.org/licenses/by-nc-nd/4.0/>).

2212-6287/2289

<https://doi.org/10.1016/j.eats.2022.02.026>

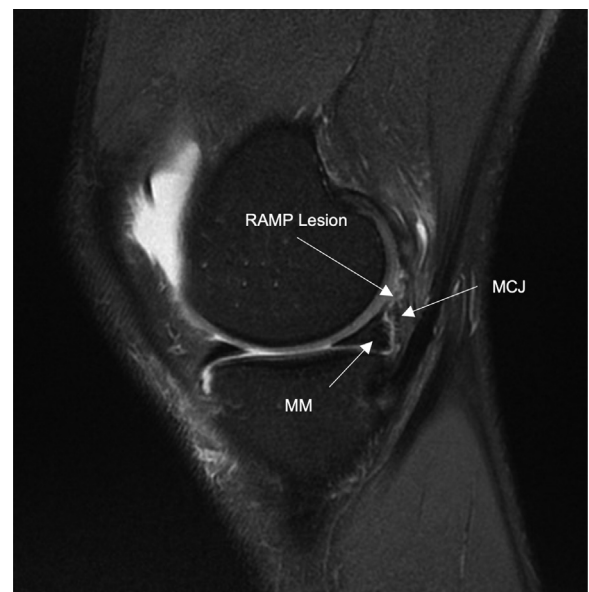


Fig 1. Typical MRI sign of a ramp lesion in an ACL-deficient knee. In this sagittal slice MRI of the right knee, a hyper T2-weighted signal can be observed at the meniscocapsular junction of the posterior part of the medial meniscus posterior horn. Abbreviations: ACL, anterior cruciate ligament; MCJ, meniscocapsular junction; MM, medial meniscus; MRI, magnetic resonance imaging.

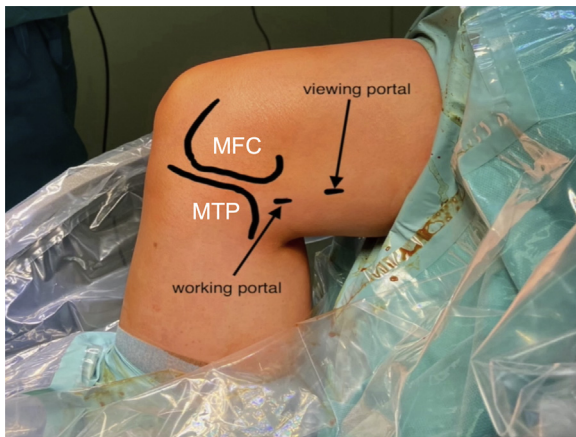


Fig 2. Landmarks and position of the posteromedial portals. The patient is lying supine on the operating table with the operated limb hanging toward the floor in a leg holder at 90° knee flexion. In this right knee, the viewing portal is posterior to the posterior femoral cortex and proximal to the posterior border of the medial femoral condyle. The working portal is located 3 to 4 cm more distal and slightly posterior to the viewing portal, at the height of the joint line. Abbreviations: MFC, medial femoral condyle; MTP, medial tibial plateau.

the anteroposterior (AP) and rotational stability of the knee.^{4,5}

In vitro studies have shown that ramp repair can restore normal joint kinematics.^{6,7} Common techniques include all-inside technique or repair through a single PM portal.⁸⁻¹⁰ The latter involves visualizing the PM

compartment through the intercondylar notch, which limits the detection and characterization of ramp lesions and makes triangulation between the scope and the instrumental PM portal challenging. A second PM portal allowing for direct visualization of the PM compartment may thus facilitate both the identification and repair of these lesions. We introduce here this 2-portal technique for suturing ramp lesions.

Technique

Patient Positioning, Standard Portals, and Landmarks

The patient is lying supine on the operating table with the operated limb hanging toward the floor in a leg holder at 90° of knee flexion. A tourniquet is placed on the proximal thigh. During the meniscal procedure, the latter is not inflated. For external identification of the position of the 2 PM portals, 3 landmarks are used: the medial femoral condyle with the posterior femoral cortex, the medial tibial plateau, and the joint line. The viewing portal is proximal to the medial femoral condyle and posterior to the posterior femoral cortex, and the working portal is about 3 to 4 cm more distal, at the height of the joint line (Fig 2, Video 1).

Standard Arthroscopic Examination

Standard anteromedial and anterolateral portals are used. Arthroscopic examination of both anterior

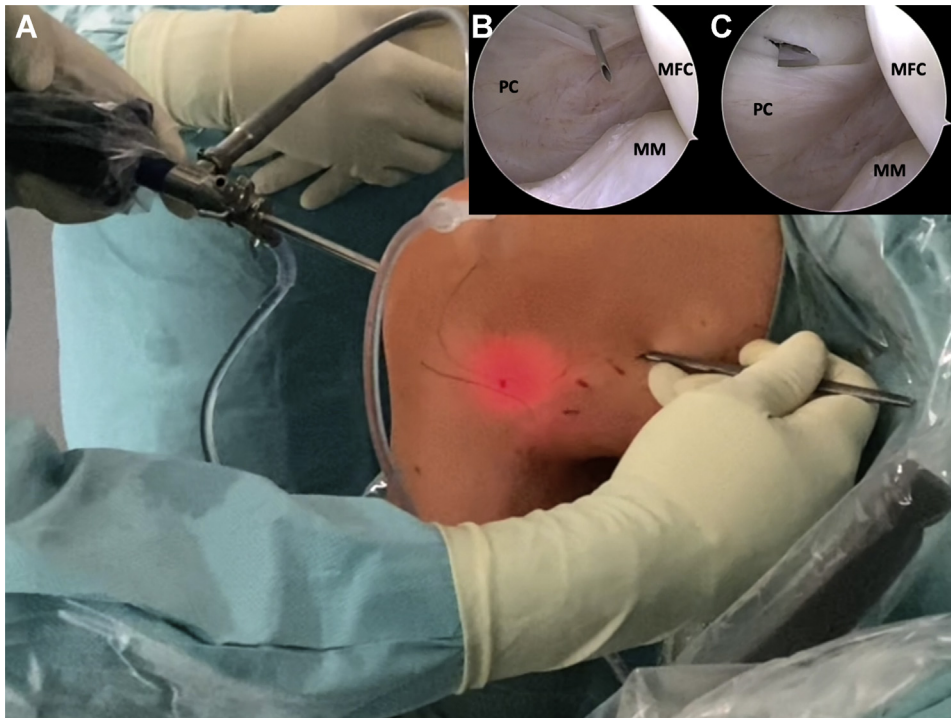
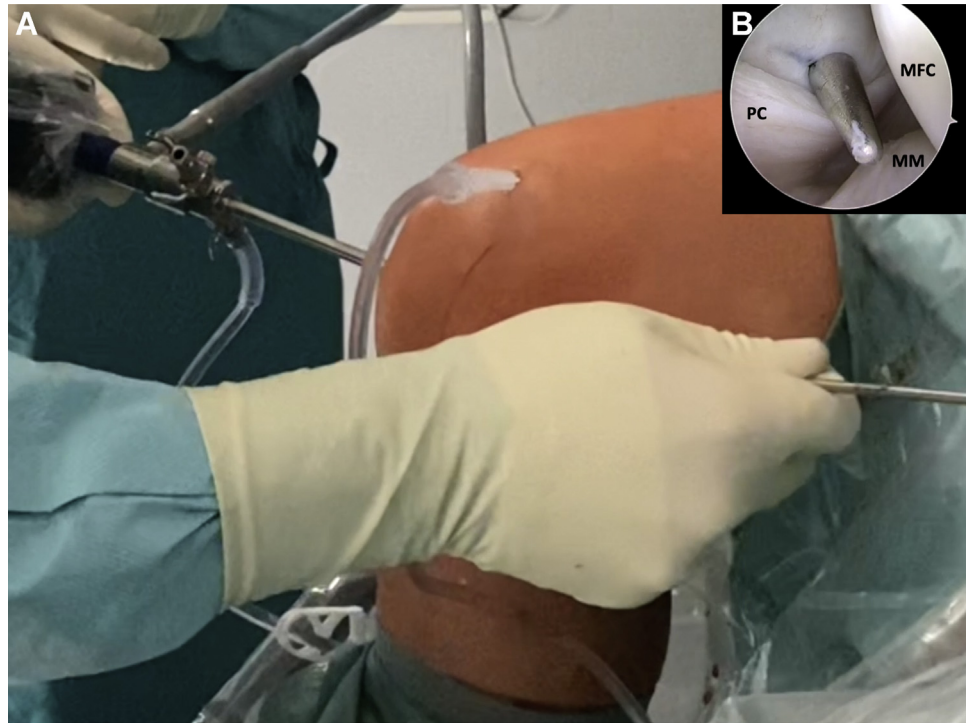


Fig 3. Viewing portal approach via the transnotch view. This is a right knee at 90° knee flexion (A). The entry of the viewing portal is identified through a transnotch articular view with the help of a needle and transillumination to protect from saphenous vessel injury (B). A no. 11 blade scalpel is used for the skin incision (C). Abbreviations: MFC, medial femoral condyle; MM, medial meniscus; PC, posterior capsule.

Fig 4. The use of a switching stick to help the introduction of the trocar and the camera into the posteromedial viewing portal. This a right knee at 90° flexion (A). After skin incision and dissection with scissors at the posteromedial viewing portal, a switching stick is used to help introduce the trocar and the camera into the posteromedial viewing portal (B). Abbreviations: MM, medial meniscus; PC, posterior capsule.



tibiofemoral compartments is started with standard anteromedial and anterolateral portals. To test the stability of the medial meniscus, a probe is used to palpate the meniscus and verify whether any tear or instability can be identified and if the posterior horn can be displaced under the medial femoral condyle. To further explore the PM compartment, a transnotch view is performed. With the knee at 90° flexion, a blunt trocar is introduced from the anterolateral portal. The anterior aspect of the medial femoral condyle is identified, and the trocar is advanced through the intercondylar notch,

between the medial femoral condyle and the medial border of the posterior cruciate ligament (PCL).

Viewing Portal Approach and Direct Visualization of the Ramp

The PM viewing portal is established with transillumination to visualize and avoid iatrogenic injuries to the saphenous vein and nerve. Using the transnotch view, the entry point of the viewing portal is identified with the help of a needle. Its position should be cranial to the easily identifiable PM synovial fold (Fig 3 A).

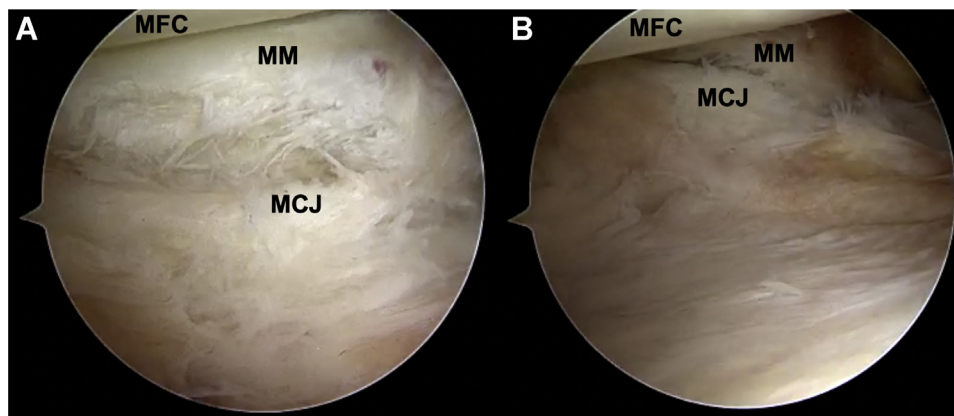


Fig 5. Direct visualization of the posteromedial corner and a ramp lesion through the posteromedial viewing portal (right knee). The camera is in the posteromedial viewing portal. The flexion-extension movement of the knee helps to reveal ramp lesions. (A) Posteromedial view of a ramp lesion at 90° flexion. (B) Posteromedial view of a ramp lesion at 20° extension. Abbreviations: MCJ, meniscocapsular junction; MFC, medial femoral condyle; MM, medial meniscus.

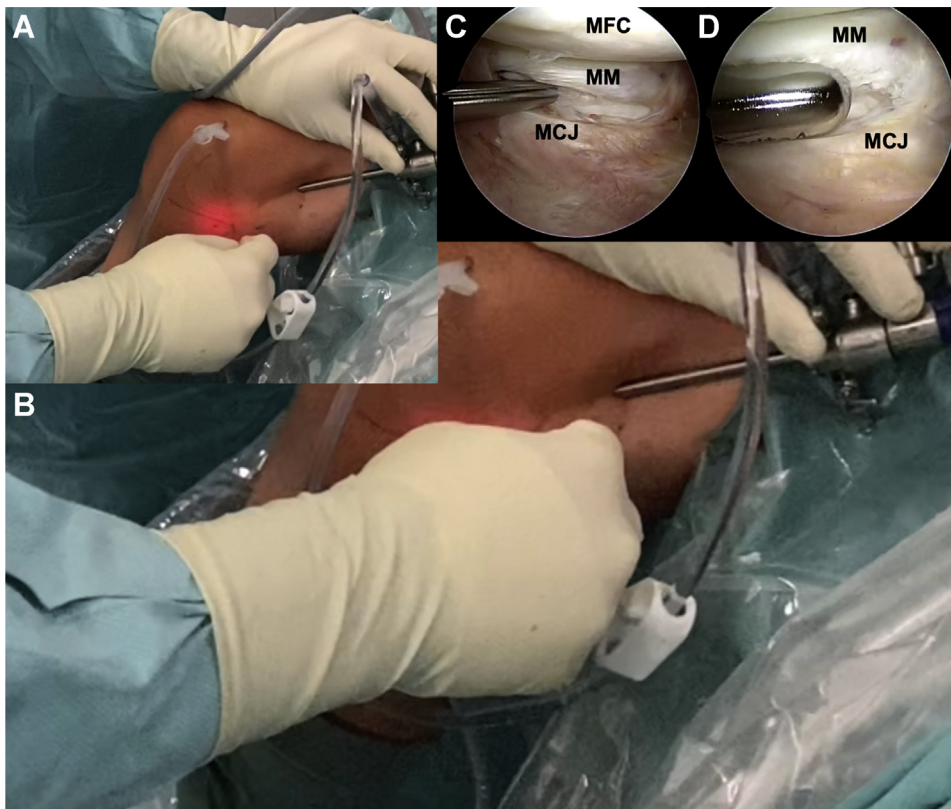


Fig 6. Instrumental portal approach, right knee at 90° flexion. The camera is in the posteromedial viewing portal. The entry of the working portal is identified with a needle and the use of trans illumination to protect from saphenous vessel injury (A). A no. 11 blade scalpel is used for skin incision (B). The ramp lesion is probed (C) and then debrided with a shaver (D). Abbreviations: MCJ, meniscocapsular junction; MFC, medial femoral condyle; MM, medial meniscus.

Fig 7. Suture of a ramp lesion with a 90° curved hook, right knee at 90° flexion. The arthroscopic view is posteromedial with the camera in the posteromedial viewing portal, and the instruments are introduced through the posteromedial instrumental portal. The joint capsule is grasped (A). The instrument is passed through the posterior meniscal border, and the PDS 0 suture is advanced in the posterior joint space (B). After suture retrieval, a sliding knot is made using a knot pusher (C). After section of the suture, the knot can be visualized (D). Abbreviations: MCJ, meniscocapsular junction; MFC, medial femoral condyle; MM, medial meniscus.

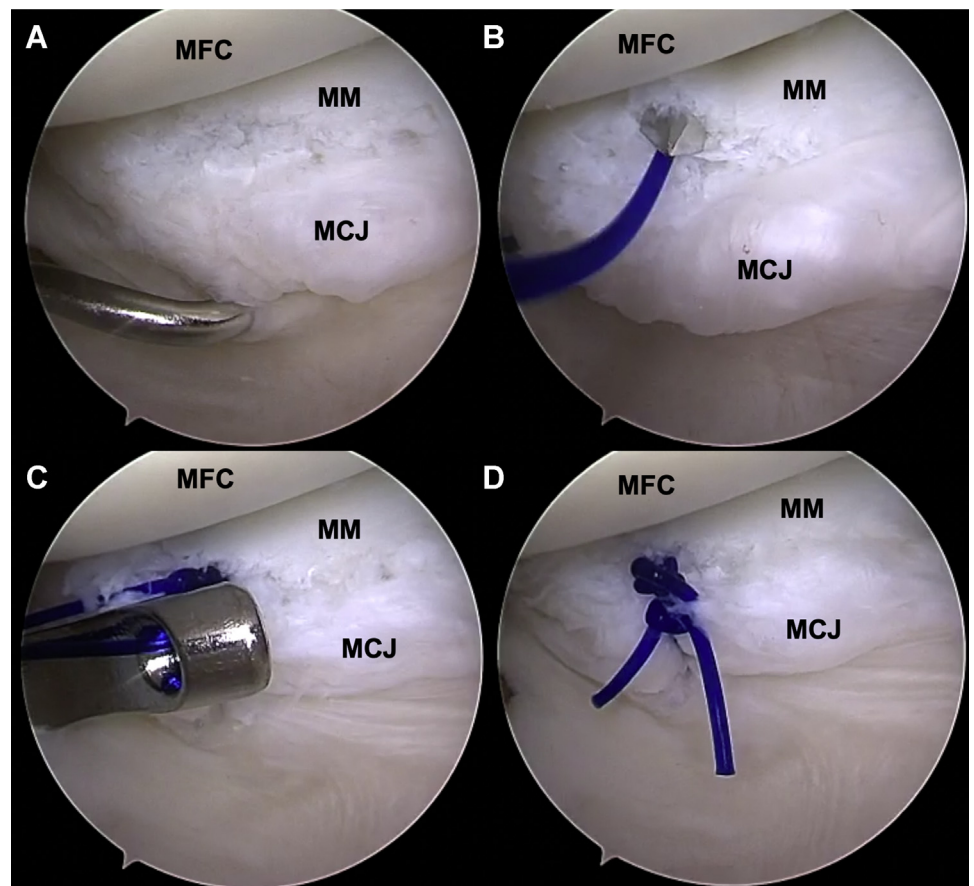
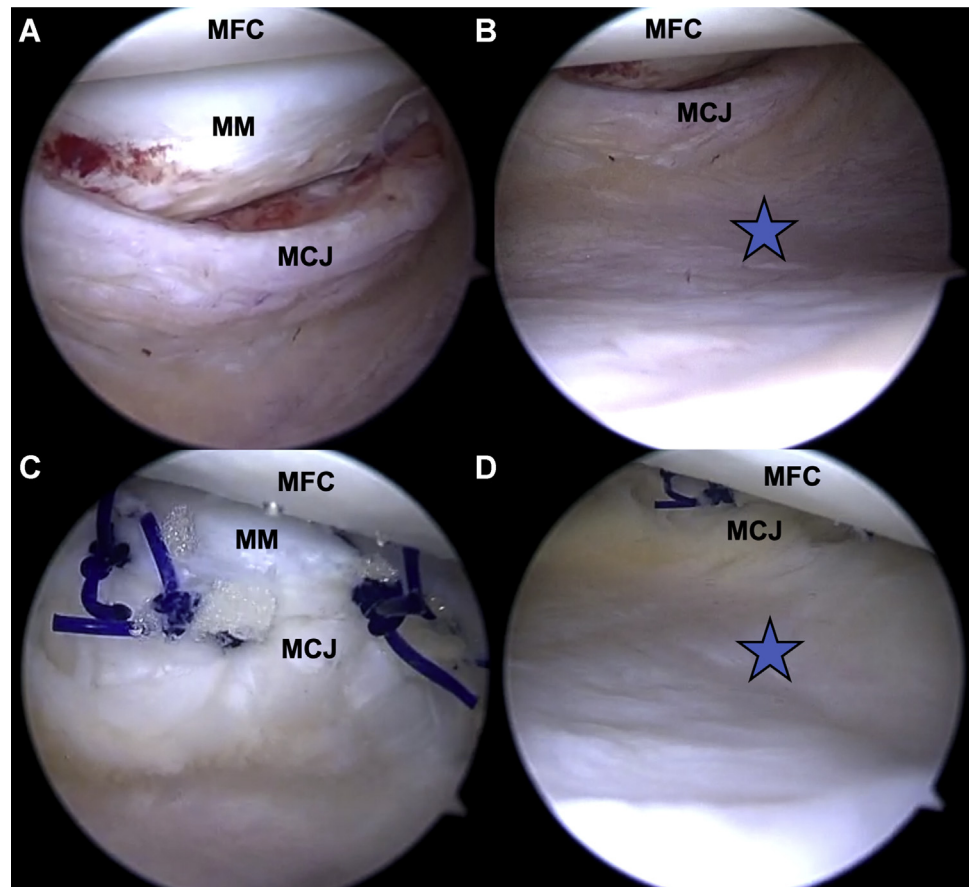


Fig 8. Posteromedial view before and after repair of a ramp lesion, right knee at 90° flexion. The camera is in the posteromedial viewing portal. Before repair, the ramp lesion is observed at 90° (A) and 20° (B) knee flexion. A cleft between the posterior wall of the medial meniscus and the ramp tissue can be identified in both positions. After repair, posteromedial view at 90° (A) and 20° (B) knee flexion. The blue star indicates adequate tensioning of the posterior capsule by the repair (B and D). Abbreviations: MCJ, meniscocapsular junction; MFC, medial femoral condyle; MM, medial meniscus.



Once the entry point and direction have been validated, a no. 11 blade scalpel is used for skin, subcutaneous and capsular incisions (Fig 3 B) under arthroscopic control. A trocar placed on a switching stick is then introduced into the PM portal (Fig 4). After removal of the latter, the camera can be introduced into the PM viewing portal over the switching rod. It allows for complete visualization of the ramp as well as a full identification of the mediolateral extension of the lesion. The

application of several flexion-extension movements of the knee helps identifying the stability of the ramp lesion and to see if the ramp tissue is separated from the posterior wall of the medial meniscus (Fig 5).

Working Portal Approach

The PM working portal is also established with transillumination to visualize and avoid iatrogenic injuries to the saphenous structures. The camera is left in

Table 1. Pearls and Pitfalls

Pearls

- Perform the transnotch view
- Use a needle and transillumination to identify the entry of the viewing portal
- The portal should be placed proximally to the posteromedial synovial fold
- Use a no. 11 blade scalpel for the incision and complete subcutaneous dissection
- Use a switching stick to facilitate introducing the trocar into the viewing portal
- Have a complete visualization of the mediolateral extension of the ramp lesion
- With a flexion-extension movement of the knee, evaluate the adherence of the posterior capsule to the posterior horn of the medial meniscus
- Use a needle and repeat the portal placement procedure to create the more distal working portal at the height of the joint line

Pitfalls

- Having 2 PM portals too close to each other risks a collision of the arthroscope and the working instruments
- Having the viewing portal too close to the joint line, leaving no place for the working portal
- Having the viewing portal within the synovial fold, which impairs the view of the ramp by soft tissue interposition

the PM viewing portal. The entry point of the working portal is identified with a needle placed proximally and posteriorly to the PM border of the tibial plateau at the height of the joint line. It is located approximately 3 to 4 cm posteriorly and distally to the viewing portal (Fig 6 A). A no. 15 blade scalpel is used for skin incision (Fig 6 B), and the dissection of subcutaneous soft tissue is completed with dissecting scissors under arthroscopic control.

Ramp Lesion Repair

Direct visualization through the PM viewing portal and palpation with the arthroscopic probe through the PM working portal allows identification of the ramp lesion as well as its mediolateral extension (Fig 6 C). In some cases, its full extent may become visible only after debridement with a 5-mm shaver (Fig 6 D) because it may be partially covered by synovial tissue. Once the decision for repair has been made, appropriate instruments with curved needles need to be prepared (e.g. Spectrum; Conmed Linvatec, Largo, FL). Depending on the location of the repair site, either a left- or right-angled 60° or 90° curved hook is chosen, and the repair instrument is loaded with a PDS 0 suture. The lesion is repaired from medial to lateral. Care should be taken to reposition the ramp tissue adequately to allow for an anatomic repair, and iatrogenic cartilage injuries of the tibial plateau or femoral condyle should be avoided.

First the distal, posterior part of the ramp tissue is grasped with the curved hook (Fig 7 A). It is then passed through the posterior wall of the meniscus (Fig 7 B). The PDS 0 suture is advanced to the posterior compartment and retrieved with a grasping forceps. A sliding knot is applied (Fig 7 C, D), and stitches are repeated every 4 to 5 mm (2 to 3 stitches are usually necessary for a complete repair). At the end of the procedure, the stability of the repair is tested with a repetitive flexion-extension movement, also assessing adequate tension of the posterior joint capsule (Fig 8).

Discussion

Current techniques to repair ACL-associated medial meniscus ramp lesions involve visualizing the PM compartment through an intercondylar notch view, making triangulation between the arthroscope and the instrumental PM portal challenging. To allow for better identification of the extent of the ramp lesion and an easier repair—and hence overcoming the learning curve of previous repair techniques⁹—a 2-portal posteromedial approach is proposed. The creation of a PM viewing portal provides a direct and better view of the area of the medial meniscus ramp as well as a better identification of the lesion (Table 1).

The static view obtained of the ramp, the meniscocapsular junction, and the medial femoral condyle is

Table 2. Advantages and Disadvantages

Advantages
Complete visualization of the ramp lesion from its medial to its central border
Both hands of the surgeon are working in line for the repair procedure, facilitating triangulation
Better visualization of the tension of the posterior capsule after repair
Disadvantages
Additional posteromedial incision
Additional risk of iatrogenic injury to saphenous structures

similar to an anterior view of the shoulder with the labrum and the humeral head. Dynamic and repetitive flexion-extension movements provide understanding of the stability of the ramp lesion, with frequent observation of a cleft between the posterior wall of the medial meniscus or appearing during knee extension. The PM working portal makes it possible to probe the ramp lesion and gain further information on its stability and extension, especially if it is covered by synovial tissue, which may then be easily debrided with a shaver. The PM positioning of the 2 portals places the suture hook in line with the arthroscope and thus facilitates triangulation and repair of the ramp lesion.

In 2004, Ahn et al.¹¹ described an all-inside suture technique of the PHMM using 2 different posteromedial portals. However, the authors used the second PM portal as a second working portal and not to place the arthroscope. More recently, Christopher et al.¹² presented a similar procedure for complex posteromedial arthroscopy cases, but the authors focused their report on posterior mass resection and used a 70° arthroscope.

The main disadvantage of using 2 posteromedial portals is the risk of a iatrogenic injury of the saphenous structures.¹³ However, we describe in detail how to place the portals and thus minimize the risk. The PM portals are located in a safe zone, about 1.5 cm from the neurovascular structures, as described by McGinnis et al.¹⁴ We have been using this technique for >5 years without any complication (Table 2). It has both facilitated and improved medial ramp repair by allowing a more precise description of the lesion and a more anatomic repair.

Repair of ACL-associated medial meniscus ramp lesions through a transnotch viewing portal and a single posteromedial working portal is a challenging procedure. It does not allow for complete visualization of the lesion and bears a significant learning curve. Therefore, a technique with 2 PM portals has been developed for routine ramp repair. It improves visualization of the lesion and allows for an identification of its stability and a more anatomic repair. Likewise, by placing the instruments in line with the arthroscope, it is more intuitive and facilitates the procedure.

References

1. Greif DN, Baraga MG, Rizzo MG, et al. MRI appearance of the different meniscal ramp lesion types, with clinical and arthroscopic correlation. *Skeletal Radiol* 2020;49:677-689.
2. Kunze KN, Wright-Chisem J, Polce EM, DePhillipo NN, LaPrade RF, Chahla J. Risk factors for ramp lesions of the medial meniscus: A systematic review and meta-analysis. *Am J Sports Med* 2021;49:3749-3757.
3. Sonnery-Cottet B, Conteduca J, Thaumat M, Gunepin FX, Seil R. Hidden lesions of the posterior horn of the medial meniscus: A systematic arthroscopic exploration of the concealed portion of the knee. *Am J Sports Med* 2014;42:921-926.
4. Mouton C, Magosch A, Pape D, Hoffmann A, Nührenbörger C, Seil R. Ramp lesions of the medial meniscus are associated with a higher grade of dynamic rotatory laxity in ACL-injured patients in comparison to patients with an isolated injury. *Knee Surg Sports Traumatol Arthrosc* 2020;28:1023-1028.
5. Peltier A, Lording T, Maubisson L, Ballis R, Neyret P, Lustig S. The role of the meniscotibial ligament in posteromedial rotational knee stability. *Knee Surg Sports Traumatol Arthrosc* 2015;23:2967-2973.
6. DePhillipo NN, Moatshe G, Brady A, et al. Effect of meniscocapsular and meniscotibial lesions in ACL-deficient and ACL-reconstructed knees: A biomechanical study. *Am J Sports Med* 2018;46:2422-2431.
7. Stephen JM, Halewood C, Kittl C, Bollen SR, Williams A, Amis AA. Posteromedial meniscocapsular lesions increase tibiofemoral joint laxity with anterior cruciate ligament deficiency, and their repair reduces laxity. *Am J Sports Med* 2016;44:400-408.
8. Negrín R, Reyes NO, Iñiguez M, Pellegrini JJ, Wainer M, Duboy J. Meniscal ramp lesion repair using an all-inside technique. *Arthrosc Tech* 2018;7:e265-e270.
9. Thaumat M, Fayard JM, Guimaraes TM, Jan N, Murphy CG, Sonnery-Cottet B. Classification and surgical repair of ramp lesions of the medial meniscus. *Arthrosc Tech* 2016;5:e871-e875.
10. Acosta J, Ravaei S, Brown SM, Mulcahey MK. Examining techniques for treatment of medial meniscal ramp lesions during anterior cruciate ligament reconstruction: A systematic review. *Arthroscopy* 2020;36:2921-2933.
11. Ahn JH, Kim SH, Yoo JC, Wang JH. All-inside suture technique using two posteromedial portals in a medial meniscus posterior horn tear. *Arthroscopy* 2004;20:101-108.
12. Christopher ZK, Dulle DL, Makovicka JL, Chhabra A. Dual-posteromedial portal technique for complex arthroscopy in the posterior knee. *Arthrosc Tech* 2021;10:e257-e261.
13. Toanen C, Sanchez M, Beaufile P, Pujol N. Ramp lesion repair via dual posteromedial arthroscopic portals: A cadaveric feasibility study. *Orthop Traumatol Surg Res* 2021:103175.
14. McGinnis MD, Gonzalez R, Nyland J, Caborn DNM. The posteromedial knee arthroscopy portal: A cadaveric study defining a safety zone for portal placement. *Arthroscopy* 2011;27:1090-1095.