



HAL
open science

Pomalidomide-induced lung injury: A case report

Alexandre Vivien, Julien Ancel, Sophie Godet, Sandra Dury, Jeanne-Marie Perotin, Gaetan Deslee, Claire Launois

► **To cite this version:**

Alexandre Vivien, Julien Ancel, Sophie Godet, Sandra Dury, Jeanne-Marie Perotin, et al.. Pomalidomide-induced lung injury: A case report. *Medicine*, 2023, 102 (2), pp.e32473. 10.1097/MD.00000000000032473 . hal-03955507

HAL Id: hal-03955507

<https://hal.univ-reims.fr/hal-03955507>

Submitted on 25 Jan 2023

HAL is a multi-disciplinary open access archive for the deposit and dissemination of scientific research documents, whether they are published or not. The documents may come from teaching and research institutions in France or abroad, or from public or private research centers.

L'archive ouverte pluridisciplinaire **HAL**, est destinée au dépôt et à la diffusion de documents scientifiques de niveau recherche, publiés ou non, émanant des établissements d'enseignement et de recherche français ou étrangers, des laboratoires publics ou privés.

Pomalidomide-induced lung injury

A case report

Alexandre Vivien, MD^{a,*} , Julien Ancel, MD^{a,c}, Sophie Godet, MD^b, Sandra Dury, MD^a, Jeanne-Marie Perotin, MD, PhD^{a,c}, Gaetan Deslee, MD, PhD^{a,c}, Claire Launois, MD, PhD^{a,c}

Abstract

Rationale: Pomalidomide is an immunomodulatory imide drug used in multiple myeloma and in Kaposi sarcoma.

Patient concerns: A 72-years-old male, treated for multiple myeloma with dexamethasone, pomalidomide and daratumumab, presented dyspnea, hypoxemia, biological inflammatory syndrome, ground glass opacities on computed tomography scan (CT-scan) and lymphocytic and eosinophilic alveolitis, with no specific cytologic or microbiological findings, 2 months after pomalidomide initiation.

Intervention and outcome: Antibiotics were started after bronchoscopy. No improvement was noted in dyspnea and biological inflammatory syndrome after 5 days of treatment. Pomalidomide was then discontinued, with continuation of Daratumumab-Dexamethasone, resulting in a rapid recovery of symptoms and CT-scan anomalies. No recurrence of dyspnea was observed during the 15 months of follow-up.

Diagnoses: Pomalidomide-induced lung injury

Lessons: Pomalidomide-induced lung injury is a rare and serious adverse event that can occur early after Pomalidomide introduction. As pomalidomide use is increasing, the identification of drug toxicity as a possible cause of lung injury appears important. We report a rapid recovery of symptoms and CT-scan anomalies after pomalidomide discontinuation.

Abbreviations: CT-scan = computed tomography scan, IMiD = immunomodulatory imide drug, MM = multiple myeloma.

Keywords: lung injury, multiple myeloma, pomalidomide, side effect

1. Introduction

Pomalidomide is a thalidomide analogue and immunomodulatory imide drug (IMiD). It is used in combination with low-dose dexamethasone for the treatment of patients with relapsed and/or refractory multiple myeloma (MM) who have received at least 2 previous lines of treatment,^[1] including Lenalidomide and a proteasome inhibitor.^[2] Recently, its indication was extended to adult patients with Acquired Immune Deficiency Syndrome-related Kaposi sarcoma after failure of antiretroviral therapy and Kaposi sarcoma in adult patients who are Human Immunodeficiency Virus-negative.^[3,4]

Here, we reported a case of pomalidomide-induced lung injury.

2. Case presentation

A 72-years-old male patient undergoing treatment for MM was admitted for progressive worsening of dyspnea without fever for 3 weeks.

His past medical history included arterial hypertension treated with Losartan, Hydrochlorothiazide and Atenolol and a MM diagnosed 2 years ago. MM was initially treated with

melphalan/prednisone/velcade for 11 months then ixazomib/lenalidomide/dexamethasone for 9 months, both stopped for relapses. Two months before admission, a new MM chemotherapy line including daratumumab/pomalidomide/dexamethasone was started. There was no history of pulmonary disease and the patient had stopped smoking 40 years ago (10 pack-years).

On clinical examination, the patient exhibited dyspnea for any exercise. No cough or chest pain was described. He was afebrile. The auscultation of chest showed normal vesicular sounds without crackles.

Chest computed tomography (CT)-scan showed multiple tiny nodules randomly distributed in both lungs, associated with apical ground glass opacities (Fig. 1A). Laboratory tests revealed an elevation of inflammatory markers (c-reactive protein 45 mg L⁻¹) associated to a known stable bicytopenia (white blood cells 0.8 giga L⁻¹, hemoglobin 8.2 g dL⁻¹). The arterial blood gases showed moderate hypoxemia (room air PaO₂: 72 mm Hg) and hypocapnia (PaCO₂: 30 mm Hg). Flexible bronchoscopy was performed before starting any therapeutic intervention. Bronchoalveolar lavage cell count found an elevation of lymphocytes and eosinophils percentage (168,000 cells mL⁻¹, 44% lymphocytes, 30.5% macrophages,

The authors have no funding and conflicts of interest to disclose.

Data sharing not applicable to this article as no datasets were generated or analyzed during the current study.

^a Department of Respiratory Diseases, Reims University Hospital, Reims, France,

^b Department of Hematology, Reims University Hospital, Reims, France, ^c INSERM UMR-S 1250 "Pathologies Pulmonaires Et Plasticité Cellulaire," University of Reims Champagne-Ardenne, Reims, France.

* Correspondence: Alexandre Vivien, Department of Respiratory Diseases, Reims University Hospital, Reims, France (e-mail: alexandrevivienpro@gmail.com).

Copyright © 2023 the Author(s). Published by Wolters Kluwer Health, Inc.

This is an open access article distributed under the Creative Commons Attribution License 4.0 (CCBY), which permits unrestricted use, distribution, and reproduction in any medium, provided the original work is properly cited.

How to cite this article: Vivien A, Ancel J, Godet S, Dury S, Perotin J-M, Deslee G, Launois C. Pomalidomide-induced lung injury: A case report. *Medicine* 2023;102:2(e32473).

Received: 25 November 2022 / Accepted: 7 December 2022

<http://dx.doi.org/10.1097/MD.00000000000032473>

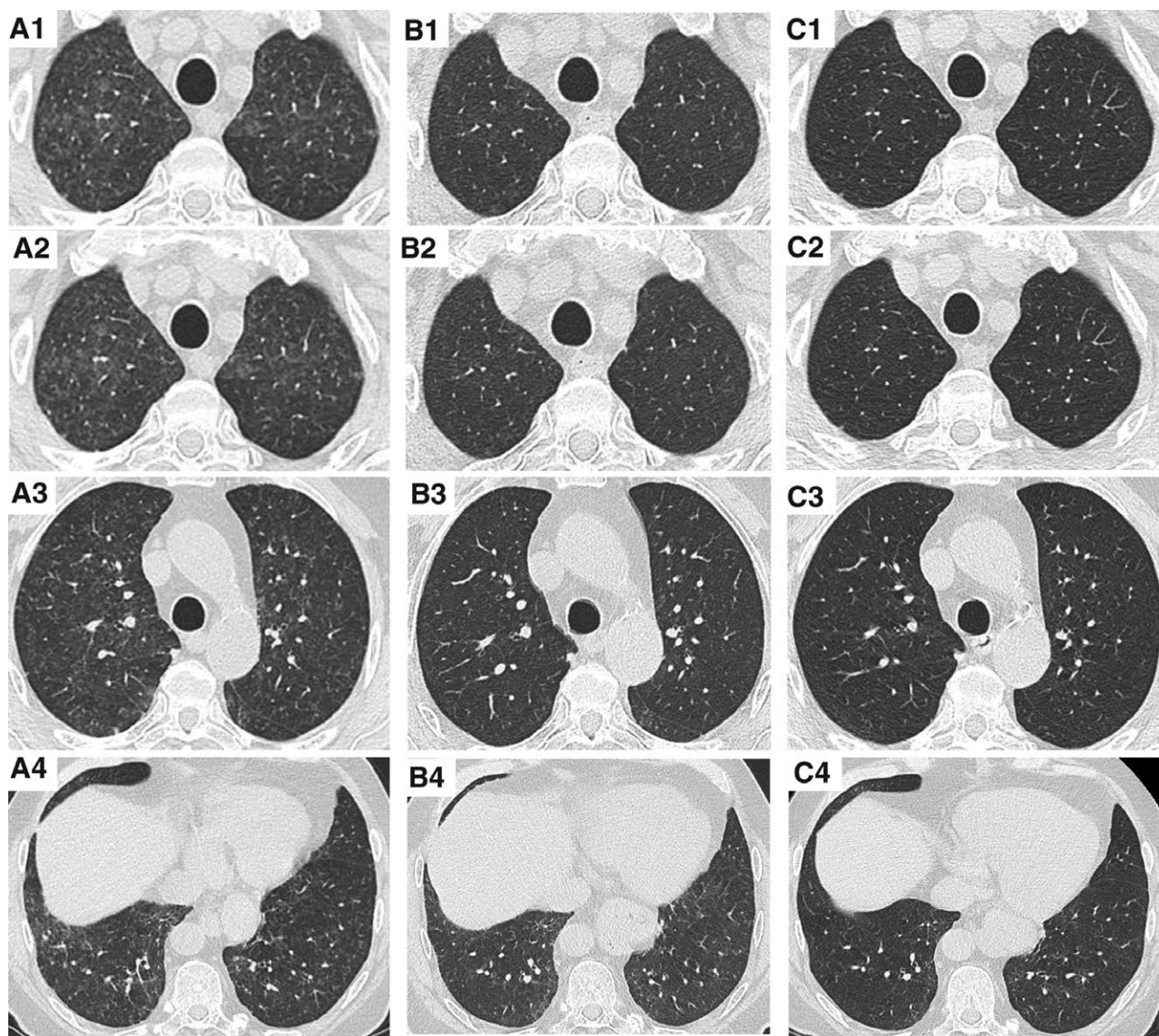


Figure 1. High resolution CT. Chest CT-scan at the initial presentation (A₁, A₂, A₃, A₄), after one month of pomalidomide discontinuation (B₁, B₂, B₃, B₄), and after four months of pomalidomide discontinuation (C₁, C₂, C₃, C₄). CT = computed tomography. CT-scan = computed tomography scan.

25% eosinophils and 0.5% neutrophils) with no specific cytologic or microbiological findings. Pulmonary function tests revealed a low alveolar–capillary membrane diffusing capacity (carbon monoxide diffusing capacity of the lung 37% of predicted value with a restrictive pattern (total lung capacity 5.230 L; 73% of predicted value).

No improvement in dyspnea and biological inflammatory syndrome was obtained after 5 days of antibiotics that were started after bronchoscopy. Because pomalidomide-associated lung injury was suspected, pomalidomide was discontinued, with continuation of daratumumab-dexamethasone. No steroid treatment was introduced. Dyspnea gradually decreased and finally disappeared. One month later, PaO₂ was normal (room air PaO₂: 96 mm Hg; PaCO₂: 34 mm Hg) and chest computed tomography scan (CT-scan) showed disappearance of multiple tiny nodules and of most ground glass opacities (Fig. 1B). At 4 months, carbon monoxide diffusing capacity of the lung also improved (63% of predicted value) with normalization of both total lung capacity (7.690 L; 108% of predicted value) and chest CT-scan (Fig. 1C). Because of the diagnosis of pomalidomide-associated lung injury, pomalidomide was definitely stopped. Pomalidomide, was switched to cyclophosphamide.

Under this treatment, his general condition worsened leading to several other treatment strategies. Successive different treatment lines failed to control MM evolution. The patient finally died 15 months after the pulmonary event. There was no recurrence of dyspnea during this medical follow-up.

Because of the retrospective non-interventional design and anonymous management of the data, informed consent of the patient for inclusion was waived, as approved by the French national commission for personal data protection (Comité National de l'Information et des Libertés) (n°2049775 v 0) according to the Jardé law in France.

3. Discussion

The mechanisms of action of pomalidomide include angiogenesis inhibition, immunomodulation, impeding cytokine production, and interaction with bone marrow and tumor microenvironment.^[5] It interferes with cellular cycle and apoptosis.^[6] Most of these mechanisms are common with the other IMiDs derived from thalidomide.^[7,8]

The major pulmonary adverse event reported with pomalidomide is infectious pneumonia^[9–11] (occurs in 15 to 20% of treated

patients), related to neutropenia. Thromboembolic events, which are also reported with Lenalidomide and Thalidomide, occur in 1% of patients treated with pomalidomide.^[12] Although no evidence of the drug toxicity was highlighted in randomized clinical trials, drug-mediated lung injury related to thalidomide, lenalidomide and pomalidomide have been described in a few case reports,^[12-15]

The 7 case reports^[16-21] and the present case report of pomalidomide-induced lung injury are summarized in Table 1. These cases present several similarities. Respiratory symptoms seem to be abrupt or rapidly progressive for most of the cases which is similar to our case report. Mid to upper ground glass lung opacities are the most frequent radiological pattern. Elevated bronchoalveolar lavage lymphocytes and/or eosinophils percentages have been reported, as well as alveolar hemorrhage. Pulmonary infection was ruled out in these cases. Pomalidomide discontinuation was associated in all the cases with a dramatic and rapid improvement, with rare residual pulmonary fibrosis. Only 1 case reported by Gajic^[19] showed fibrotic peripheral reticular abnormalities 3 weeks after Pomalidomide discontinuation, with no later CT-scan performed. As the risk of recurrence of lung injury with the reintroduction of pomalidomide seems to be high (3 of the 4 cases previously reported), we decided to not re-use this treatment.

The latency of lung injury onset since the pomalidomide introduction between 6 days to 22 months. In our case, the time exposure to Pomalidomide was relatively short (2 months). This could be explained by an early diagnosis of lung injury, as the clinical involvement and the extent of CT abnormalities were mild in our case. Then, as there is close structural homology between IMiDs, it is conceivable that prior IMiD exposure could prime patient's immune system for hypersensitivity to Pomalidomide. Our patient was previously exposed to Lenalidomide for 11 months. We note that the reported case

with the latest onset of lung injury (22 months) did not have a previous exposure to another IMiD. However, as there are a low number of published reports on pomalidomide-induced lung injury, which do not all report previous dosage and/or duration of exposure to other IMiDs, it is unclear whether prior IMiD exposure could interfere with the time to onset of lung injury. It is also unknown whether lung injury would occur with other IMiDs and would thus be considered a "class effect." Based on these observations, we suggest that when possible, it is probably safe to avoid other IMiDs use after the occurrence of pomalidomide-induced lung injury.

4. Conclusion

Pomalidomide-induced lung injury is an uncommon but serious adverse event that can occur early after Pomalidomide introduction. With increasing use of pomalidomide, recognition of drug toxicity as a possible cause of lung injury is important, particularly given that we noticed a swift reversibility of lesions and symptoms at the pomalidomide discontinuation.

Author contributions

Conceptualization: Alexandre Vivien, Julien Ancel, Sophie Godet, Sandra Dury, Jeanne-Marie Perotin, Gaetan Deslee, Claire Launois.

Investigation: Alexandre Vivien, Julien Ancel, Sophie Godet, Sandra Dury, Jeanne-Marie Perotin, Gaetan Deslee, Claire Launois.

Resources: Alexandre Vivien, Julien Ancel, Sophie Godet, Sandra Dury, Jeanne-Marie Perotin, Gaetan Deslee, Claire Launois.

Visualization: Alexandre Vivien, Julien Ancel, Sophie Godet, Sandra Dury, Jeanne-Marie Perotin, Gaetan Deslee, Claire Launois.

Table 1
Summary of published reports on Pomalidomide-induced lung injury and clinical patterns.

| Author, yr | Clinical symptoms | Latency from Pomalidomide introduction | CT-scan findings | BAL results | Therapeutic management t | Outcome |
|-----------------------------|--|--|--|---|--|---|
| Geyer, 2011 ^[16] | -abrupt dyspnea -O ₂ desaturation | 480 d | patchy ground glass opacities mid to upper lungs with consolidative characteristics | considered as normal | antibiotics + Pomalidomide discontinuation | -rapid improvement -relapse at reintroduction |
| Geyer, 2011 ^[16] | -abrupt dyspnea -fever -O ₂ desaturation | 120 d | patchy ground glass opacities mid to upper lungs with diffuse central lobular fluffy infiltrates | 43% macrophages 5% lymphocytes | Pomalidomide discontinuation + steroid treatment | -rapid improvement -reintroduction without recurrence |
| Tello, 2013 ^[17] | -respiratory failure -dyspnea -fever | 7 d | diffuse alveolar opacities | 45% eosinophils alveolar hemorrhage | Pomalidomide discontinuation + steroid treatment | -rapid improvement -relapse at reintroduction |
| Modi, 2015 ^[18] | -progressive dyspnea -cough -fever -O ₂ desaturation | 8 mo | ground glass opacities upper lungs | not realized | antibiotics + Pomalidomide discontinuation + steroid treatment | -progressive improvement -relapse at reintroduction |
| Gajic, 2018 ^[19] | -progressive dyspnea -O ₂ desaturation | 22 mo | ground glass opacities mid to upper lungs, fibrosis | 30% lymphocytes | Pomalidomide discontinuation + steroid treatment | -progressive resolution -fibrosis lesions |
| Kumar, 2018 ^[20] | -respiratory failure -cough -fever | unknown | consolidation of both lungs, pleural effusion | Not realized | antibiotics + antifungals + Pomalidomide discontinuation | rapid resolution |
| Icard, 2021 ^[21] | -fever -lethargy | 6 days | Ground glass opacities, diffuse interlobular thickening | 71% lymphocytes | Antibiotics + corticosteroids + Pomalidomide discontinuation | Rapid resolution |
| 2022 | -dyspnea | 2 mo | Tiny nodules, apical ground glass opacities | 44% lymphocytes, 31% macrophages, 25% eosinophils | Antibiotics + Pomalidomide discontinuation | Rapid resolution |

BAL = bronchoalveolar lavage, CT-scan = computed tomography scan.

Writing – original draft: Alexandre Vivien, Julien Ancel, Sophie Godet, Sandra Dury, Jeanne-Marie Perotin, Gaetan Deslee, Claire Launois.

Writing – review & editing: Alexandre Vivien, Julien Ancel, Sophie Godet, Sandra Dury, Jeanne-Marie Perotin, Gaetan Deslee, Claire Launois.

References

- [1] Elkinson S, McCormack PL. Pomalidomide: first global approval. *Drugs*. 2013;73:595–604.
- [2] Miguel JS, Weisel K, Moreau P, et al. Pomalidomide plus low-dose dexamethasone versus high-dose dexamethasone alone for patients with relapsed and refractory multiple myeloma (MM-003): a randomised, open-label, phase 3 trial. *Lancet Oncol*. 2013;14:1055–66.
- [3] Research C for DE and. FDA grants accelerated approval to pomalidomide for Kaposi sarcoma. FDA. Published online May 15, 2020. Available at: <https://www.fda.gov/drugs/resources-information-approved-drugs/fda-grants-accelerated-approval-pomalidomide-kaposi-sarcoma>. [Access date December 22, 2021].
- [4] Polizzotto MN, Uldrick TS, Wyvill KM, et al. Pomalidomide for symptomatic Kaposi's sarcoma in people with and without HIV infection: a phase III study. *J Clin Oncol Off J Am Soc Clin Oncol*. 2016;34:4125–31.
- [5] Ríos-Tamayo R, Martín-García A, Alarcón-Payer C, et al. Pomalidomide in the treatment of multiple myeloma: design, development and place in therapy. *Drug Des Devel Ther*. 2017;11:2399–408.
- [6] Görgün G, Calabrese E, Soydan E, et al. Immunomodulatory effects of lenalidomide and pomalidomide on interaction of tumor and bone marrow accessory cells in multiple myeloma. *Blood*. 2010;116:3227–37.
- [7] Singhal S, Mehta J, Desikan R, et al. Antitumor activity of thalidomide in refractory multiple myeloma. *N Engl J Med*. 1999;341:1565–71.
- [8] Schey SA, Fields P, Bartlett JB, et al. Phase I study of an immunomodulatory thalidomide analog, CC-4047, in relapsed or refractory multiple myeloma. *J Clin Oncol Off J Am Soc Clin Oncol*. 2004;22:3269–76.
- [9] Fangusaro J, Mitchell DA, Kocak M, et al. Phase 1 study of pomalidomide in children with recurrent, refractory, and progressive central nervous system tumors: a pediatric brain tumor consortium trial. *Pediatr Blood Cancer*. 2021;68:e28756.
- [10] Mushtaq A, Iftikhar A, Hassan H, et al. Pomalidomide-based regimens for treatment of relapsed and relapsed/refractory multiple myeloma: systematic review and meta-analysis of phase 2 and 3 clinical trials. *Clin Lymphoma Myeloma Leuk*. 2019;19:447–61.
- [11] Dimopoulos MA, Palumbo A, Corradini P, et al. Safety and efficacy of pomalidomide plus low-dose dexamethasone in STRATUS (MM-010): a phase 3b study in refractory multiple myeloma. *Blood*. 2016;128:497–503.
- [12] Tun HW, Johnston PB, DeAngelis LM, et al. Phase 1 study of pomalidomide and dexamethasone for relapsed/refractory primary CNS or vitreoretinal lymphoma. *Blood*. 2018;132:2240–8.
- [13] Iino M. Interstitial pneumonitis associated with the immunomodulatory drugs thalidomide and lenalidomide. *Int J Hematol*. 2012;95:223–4.
- [14] Thornburg A, Abonour R, Smith P, et al. Hypersensitivity pneumonitis-like syndrome associated with the use of lenalidomide. *Chest*. 2007;131:1572–4.
- [15] Lerch E, Györik S, Feilchenfeldt J, et al. A case of lenalidomide-induced hypersensitivity pneumonitis. *Onkologie*. 2010;33:249–52.
- [16] Geyer HL, Viggiano RW, Lacy MQ, et al. Acute lung toxicity related to pomalidomide. *Chest*. 2011;140:529–33.
- [17] Tello HCS, Bhaskar N, McKee S, et al. Diffuse alveolar hemorrhage related to pomalidomide.1.
- [18] Modi D, Mamdani H, Vettese T. Pomalidomide-induced pulmonary toxicity in multiple myeloma. *Am J Med Sci*. 2015;350:241–2.
- [19] Gajic S, Callahan EC, Brown JK, et al. Pulmonary toxicity associated with pomalidomide. *Int J Tuberc Lung Dis Off J Int Union Tuberc Lung Dis*. 2018;22:1383–6.
- [20] Kumar AS. Pomalidomide related pulmonary toxicity: a case report. *J Young Pharm*. 2018;10:487–8.
- [21] Icard BL, Singh V, Loschner AL. Pomalidomide-associated pulmonary toxicity. *Am J Ther*. 2021;28:e143–4.