



HAL
open science

A 16-year bicentric retrospective analysis of ovarian tissue cryopreservation in pediatric units: indications, results, and outcome

Marine Grellet-Grün, Béatrice Delepine, Pauline Le van Quyen, Gerlinde Avérous, Anne Durlach, Cécile Greze, Laetitia Ladureau-Fritsch, Isabelle Lichtblau, Anne-Sophie Canepa, Antoine Liné, et al.

► To cite this version:

Marine Grellet-Grün, Béatrice Delepine, Pauline Le van Quyen, Gerlinde Avérous, Anne Durlach, et al.. A 16-year bicentric retrospective analysis of ovarian tissue cryopreservation in pediatric units: indications, results, and outcome. *Frontiers in Endocrinology*, 2023, 14, 10.3389/fendo.2023.1158405 . hal-04219535

HAL Id: hal-04219535

<https://hal.univ-reims.fr/hal-04219535>

Submitted on 27 Sep 2023

HAL is a multi-disciplinary open access archive for the deposit and dissemination of scientific research documents, whether they are published or not. The documents may come from teaching and research institutions in France or abroad, or from public or private research centers.

L'archive ouverte pluridisciplinaire **HAL**, est destinée au dépôt et à la diffusion de documents scientifiques de niveau recherche, publiés ou non, émanant des établissements d'enseignement et de recherche français ou étrangers, des laboratoires publics ou privés.



Distributed under a Creative Commons Attribution| 4.0 International License



OPEN ACCESS

EDITED BY

Eleonora Porcu,
University of Bologna, Italy

REVIEWED BY

Lotte Berdiin Colmorn,
University of Copenhagen, Denmark
Konstantin Khetchoumian,
Montreal Clinical Research Institute (IRCM),
Canada

David H. Volle,
Institut National de la Santé et de la
Recherche Médicale (INSERM), France

*CORRESPONDENCE

Marius Teletin
✉ marius.teletin@igbmc.fr

RECEIVED 03 February 2023

ACCEPTED 09 August 2023

PUBLISHED 31 August 2023

CITATION

Grellet-Grün M, Delepine B,
Le Van Quyen P, Avérous G, Durlach A,
Greze C, Ladureau-Fritsch L, Lichtblau I,
Canepa A-S, Liné A, Paillard C, Pluchart C,
Pirrello O, Rongieres C, Harika G,
Becmeur F and Teletin M (2023) A 16-year
bicentric retrospective analysis of ovarian
tissue cryopreservation in pediatric units:
indications, results, and outcome.
Front. Endocrinol. 14:1158405.
doi: 10.3389/fendo.2023.1158405

COPYRIGHT

© 2023 Grellet-Grün, Delepine,
Le Van Quyen, Avérous, Durlach, Greze,
Ladureau-Fritsch, Lichtblau, Canepa, Liné,
Paillard, Pluchart, Pirrello, Rongieres, Harika,
Becmeur and Teletin. This is an open-access
article distributed under the terms of the
[Creative Commons Attribution License
\(CC BY\)](https://creativecommons.org/licenses/by/4.0/). The use, distribution or
reproduction in other forums is permitted,
provided the original author(s) and the
copyright owner(s) are credited and that
the original publication in this journal is
cited, in accordance with accepted
academic practice. No use, distribution or
reproduction is permitted which does not
comply with these terms.

A 16-year bicentric retrospective analysis of ovarian tissue cryopreservation in pediatric units: indications, results, and outcome

Marine Grellet-Grün¹, Béatrice Delepine¹, Pauline Le Van Quyen²,
Gerlinde Avérous², Anne Durlach³, Cécile Greze⁴,
Laetitia Ladureau-Fritsch⁴, Isabelle Lichtblau⁴,
Anne-Sophie Canepa¹, Antoine Liné⁵, Catherine Paillard⁶,
Claire Pluchart⁷, Olivier Pirrello⁸, Catherine Rongieres⁸,
Ghassan Harika⁹, François Becmeur¹⁰ and Marius Teletin^{4,11*}

¹Department of Reproductive Biology – Centre d'Etude et de Conservation des Oeufs et du Sperme Humain (CECOS), Centre Hospitalier Universitaire de Reims, Reims, France, ²Department of Pathology, Hôpital de Haute-pierre, Strasbourg, France, ³Department of Pathology, Centre Hospitalier Universitaire de Reims, Reims, France, ⁴Department of Reproductive Biology – Centre d'Etude et de Conservation des Oeufs et du Sperme Humain (CECOS), Centre Médico-chirurgical Obstétrique, Schiltigheim-Strasbourg, France, ⁵Department of Pediatric Surgery, Centre Hospitalier Universitaire de Reims, Reims, France, ⁶Department of Pediatric Onco-Hematology, Hôpital de Haute-pierre, Strasbourg, France, ⁷Department of Pediatric Onco-Hematology, Centre Hospitalier Universitaire de Reims, Reims, France, ⁸Department of Gynecology-Obstetric, Centre Médico-Chirurgical Obstétrique, Schiltigheim-Strasbourg, France, ⁹Department of Gynecology-Obstetric, Centre Hospitalier Universitaire de Reims, Reims, France, ¹⁰Department of Pediatric Surgery, Hôpital de Haute-pierre, Strasbourg, France, ¹¹Institut de Génétique et de Biologie Moléculaire et Cellulaire (IGBMC), Centre National de la Recherche Scientifique (CNRS UMR7104), Institut National de la Santé et de la Recherche Médicale (INSERM U1258), Université de Strasbourg (UNISTRA), Illkirch Graffenstaden, France

Background: Cancer treatments of the last decades improve the survival rate of children and adolescents. However, chemo- and radiotherapy result in gonadal damage, leading to acute ovarian failure and sterility. The preservation of fertility is now an integral part of care of children requiring gonadotoxic treatments. Ovarian tissue cryopreservation (OTC) is an effective fertility preservation option that allows long-term storage of primordial follicles, subsequent transplantation, and restoration of endocrine function and fertility. The efficacy of this technique is well-demonstrated in adults but the data are scarce for pediatric patients. Currently, OTC represents the only possibility of preserving the potential fertility in prepubertal girls.

Procedure: This is a retrospective study of OTC practice of two French centers from January 2004 to May 2020. A total of 72 patients from pediatric units underwent cryopreservation of ovarian tissue before gonadotoxic therapy for malignant or non-malignant diseases. The ovarian cortex was cut into fragments and the number of follicles per square millimeter was evaluated histologically. The long-term follow-up includes survival rate and hormonal and fertility status.

Results: The mean age of patients at OTC was 9.3 years [0.2–17] and 29.2% were postpubertal; 51 had malignant diseases and 21 had non-malignant diseases. The most frequent diagnoses included acute leukemia, hemoglobinopathies, and neuroblastoma. Indication for OTC was stem cell transplantation for 81.9% ($n = 59$) of the patients. A third of each ovary was collected for 62.5% ($n = 45$) of the patients, a whole ovary for 33.3% ($n = 24$) of the patients, and a third of one ovary for 4.2% ($n = 3$) of the patients. An average of 17 fragments [5–35] per patient was cryoconserved. A correlation was found between the age of the patients and the number of fragments ($p < 0.001$). More fragments were obtained from partial bilateral harvesting than from whole ovary harvesting ($p < 0.05$). Histological analysis of ovarian tissue showed a median of 6.0 primordial follicles/ mm^2 [0.0–106.5] and no malignant cells were identified. A negative correlation was found between age and follicular density ($p < 0.001$). Median post-harvest follow-up was 92 months [1–188]. A total of 15 girls had died, 11 were still under treatment for their pathology, and 46 were in complete remission. Of all patients, 29 (40.2%) were subjected to a hormonal status evaluation and 26 were diagnosed with premature ovarian insufficiency (POI) ($p < 0.001$). One patient had undergone thawed ovarian tissue transplantation.

Conclusion: OTC should be proposed to all girls with high risk of developing POI following gonadotoxic therapies in order to give them the possibility of fertility and endocrine restoration.

KEYWORDS

fertility preservation, children cancer, ovarian tissue cryopreservation, gonadotoxic treatment, follow up

Introduction

Cancer treatments of the last decades improve the survival rate of children and adolescents; however, chemo- and radiotherapy result in gonadal damage, leading to acute ovarian failure and sterility. The current 5-year survival rate for girls treated for cancer is more than 80%, which will lead to an increase in adult women survivors after a malignancy (1).

The preservation of fertility is now an integral part of care of children and adult female requiring gonadotoxic treatments (2). Among different methods of fertility preservation, ovarian tissue cryopreservation (OTC) followed by ovarian tissue transplantation (OTT) has proved to be a valid strategy to preserve the endocrine and reproductive functions in women with a high risk of premature ovarian failure (3–5). OTC currently represents the only method feasible in prepubertal girls (6, 7). OTC is an effective fertility preservation option not only for oncological patients but also for those with non-malignant diseases requiring bone marrow transplantation (e.g., autoimmune diseases and B-thalassemia) (8).

Since 1996 when the first OTC was proposed (9), several series of patients have been reported. However, most of these studies focus on adult patients, and data concerning pediatric populations remain scarce (6, 10–22). The absence of international registries and the lack of reported results in many centers yield a yet uncomplete picture of the outcome after OTC.

The purpose of this article is to report 16 years of experience in OTC in patients up to the age of 18 years in two different pediatric units concerning patient's characteristic and follow-up of the cohort.

Materials and methods

Patients

This is a retrospective study of OTC practice of two French pediatric centers from January 2004 to May 2020. A total of 72 patients from pediatric units underwent cryopreservation of ovarian tissue before highly gonadotoxic therapy for malignant or benign diseases. The indication of OTC was established when the treatment included the following: conditioning for autologous or allogeneic hematologic stem cell transplantation, high-dose chemotherapy, total body or pelvic irradiation, or ovariectomy.

Ovarian tissue retrieval

Ovarian tissue retrieval, performed mainly by laparoscopy or minilaparotomy, consisted of either unilateral ovariectomy or bilateral partial ovariectomy at about one-third of the organ. The ovarian tissue

was transferred to the laboratory in less than 1 h in a transport medium Leibovitz 15 (Life Technologies, Cergy Pontoise, France) on ice.

Ovarian tissue cryopreservation

The ovarian cortex was isolated from the medulla and then cut into fragments of 3×5 mm with a thickness of 1–2 mm. Each fragment was placed in a straw (CryoBioSystem) or cryotube (Nunc, Poly Labo, Strasbourg France) and then in high-security tubes (CryoBioSystem) containing 1 ml of freezing solution composed of the transport medium supplemented with 1.5 mol/L dimethylsulfoxide (Wak-Chemie Medical GmbH, Steinbach, Germany) and 0.1 mol/L sucrose, as cryoprotectant agents and 4 mg/ml HSA (Vitrolife, Göteborg, Sweden) or 10% decomplemented patient serum.

After a 30-min equilibration in freezing medium for 30 min on ice on a shaking plate, the tubes or straws were placed in a programmable freezer, and the flow temperature was $+4^{\circ}\text{C}$. Briefly, the temperature drop was initially from $2^{\circ}\text{C}/\text{min}$ to -9°C . After manual seeding, the temperature drop was resumed at a rate of $0.3^{\circ}\text{C}/\text{min}$ to -40°C . The temperature was then dropped from $10^{\circ}\text{C}/\text{min}$ to -140°C . The tubes or straws were finally immersed and stored at the temperature of liquid nitrogen.

A fragment of ovarian cortex was fixed in formalin and processed for histological analysis to evaluate the number of follicles per square millimeter and the presence/absence of malignant ovarian micro metastasis.

Studied parameters

Several characteristics including age, malignant or non-malignant disease and treatment, and histology parameters of ovarian cortex were extracted from the patients' medical records. Follow-up data and request for OTT or alternative assisted reproduction technique during follow up were also reviewed. The long-term follow-up included survival rate and hormonal and fertility status.

Results

OTC activity

Between January 2004 and May 2020, 72 patients (22 in Reims and 50 in Strasbourg) underwent cryopreservation of ovarian tissue before receiving a highly gonadotoxic treatment. Pediatric patients were referred from two university hospitals (Strasbourg University Hospital and Reims University Hospital).

Patient age

At the time of OTC, the mean age of 72 patients was 9.3 years [0.2–17] (Figure 1). The youngest patient undergoing OTC in the cohort was 2 months old (Figure 1). Out of the 72 patients, 51 were prepubertal and 21 were postpubertal. At the time of the study, the

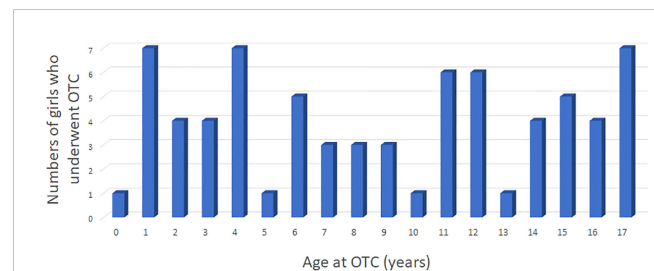


FIGURE 1

Patient series of 72 girls and adolescents younger than 18 years of age who underwent ovarian tissue cryopreservation between January 2004 to May 2020; blue bars (Strasbourg and Reims).

patients' ages ranged from 2 to 33 years, with a mean of 15.4 years. Out of 72 patients, 14 were older than 18 years (19%), and only 5 were older than 23 years (7%). Forty-seven patients were prepubertal at the time of OTC, and 22 were postpubertal, while no information was found for 3 patients regarding hormonal status.

Diagnosis

Of the 72 patients, 51 had malignant diseases (70.8%) and 21 had non-malignant diseases (29.1%) (Table 1). The most frequent diagnoses in this cohort were acute leukemia, hemoglobinopathies, and neuroblastoma. In the group of patients with malignant diseases, 25 had a hematological malignancy (34.7%) with acute lymphoblastic leukemia in 13.9% of cases ($n = 10$) and 26 had a solid tumor (36%) with neuroblastoma in 13.9% of cases ($n = 10$). Hemoglobinopathies were the most common benign disease in the cohort accounting for 21% of cases ($n = 15$). Stem cell transplantation was performed, post-OTC, in 80.6% ($n = 58$) of the patients.

Histological analysis

An average of 17 fragments [5–35] per patient was cryoconserved. A correlation was found between age and the number of fragments (Figure 2A). More fragments were obtained from partial bilateral ovariectomy than from total unilateral ovariectomy ($p < 0.05$). Histological analysis of ovarian tissue showed a median of 6.6 primordial follicles/ mm^2 [0.0–106.5] and no malignant cells were identified. A negative correlation was found between age and follicular density (Figure 2B). Mean follicular density was higher ($35.27/\text{mm}^2$) in very young patients (0–4 years old) compared to older patients (5–10, 11–14, and 15–18 years old, respectively) ($12.2/\text{mm}^2$, $4.9/\text{mm}^2$, and $9.7/\text{mm}^2$, respectively).

Patient follow-up/Mortality

Median post-harvest follow-up was 92 months [1–188]. During the follow-up period, 15 patients (8 in Reims and 7 in Strasbourg) died (20.8%). The group of patients with the highest death rate had malignant solid tumors (7 patients, 26.9%), followed by malignant

TABLE 1 Diseases of the 72 girls who underwent OTC.

		N	%	
Malignant diseases (n = 51; 71%)	Malignant hematological diseases (n = 25; 35%)	Acute lymphoblastic leukemia	10	13.9
		Hodgkin lymphoma	7	9.7
		Acute myeloblastic leukemia	6	8.3
		Non-Hodgkin lymphoma	1	1.5
		Myelodysplastic syndrome	1	1.4
	Solid malignant tumors (n = 26; 36%)	Neuroblastoma	10	13.9
		Ewing sarcoma	4	5.6
		Medulloblastoma	3	4.2
		Nephroblastoma	2	2.8
		Osteosarcoma	1	1.4
		Hypothalamic germinoma	1	1.4
		Uterine rhabdomyosarcoma	1	1.4
		Peripheral nerve sheath sarcoma	1	1.4
		Sacrococcygeal immature teratoma	1	1.4
		Thymoma	1	1.4
Desmoplastic small round cell tumor	1	1.4		
Non-malignant diseases (n = 21; 29%)	Hemoglobinopathies (n = 15; 21%)	Sickle cell disease	10	13.9
		Beta-thalassemia major	5	6.9
	Other non-malignant diseases (n = 6; 8%)	Lymphohistiocytosis	2	2.8
		Mature teratoma of the ovary	2	2.8
		Idiopathic medullary aplasia	1	1.4
		Systemic lupus erythematosus	1	1.4

hemopathies ($n = 5$, 20.0%). In the non-malignant group, 14.3% ($n = 3$) of the patients with immunodeficiency died. A total of 11 patients were still treated for their pathology (15%) and 46 were in complete remission (64%). Of all patients, 29 were subjected to a hormonal status evaluation and 26 were diagnosed with premature ovarian insufficiency (POI) (oligo/amenorrhoea for at least 4 months and FSH in the menopausal range levels >40 IU/L on two occasions >6 weeks apart) ($p < 0.001$). Among the prepubertal girls at the time of OTC, 15 remained prepubertal at the time of the study (mean age = 7.6 years), 10 died, 18 needed hormone replacement therapy (HRT), and 2 patients experienced spontaneous puberty. In the postpubertal group at the time of OTC, out of 22 patients, 5 died, and for 6 patients, no information was found regarding hormonal status. Among the remaining 11 postpubertal patients, 10 were under HRT and 1 recovered and had a normal hormonal status.

Requests for grafting of cryopreserved ovarian tissue

One patient returned to request the transplantation of cryopreserved ovarian tissue. At the time of ovarian storage, the

patient was 17 years old and had been diagnosed with stage II Hodgkin's disease. She immediately started standard chemotherapy, which consisted of six cycles of doxorubicin hydrochloride (Adriamycin), bleomycin sulfate, vinblastine sulfate, and dacarbazine (ABVD). Four weeks later, she underwent a unilateral laparoscopic oophorectomy, and the obtained tissue was divided into 20 fragments. Histological analysis revealed a follicular density of 13.8 follicles per square millimeter and no signs of malignancy.

Subsequently, the patient underwent autologous hematopoietic stem cell transplantation (HSCT). The consolidation treatment included three cycles of Mesna, Ifosfamide, Mitoxantrone, and Etoposide (MINE), and the conditioning treatment before HSCT included Carmustine, Etoposide, Cytarabine, and Melphalan (BEAM). Three months later, she received a new conditioning treatment consisting of cytarabine and melphalan, followed by 12 Gray total body irradiation (TBI) and a second autologous HSCT. Four months later, she received 20 Gray specifically targeted at the cervical region.

The patient was initiated on hormonal replacement therapy (HRT) and continued to undergo regular gynecologic and hematologic follow-up, showing no signs of disease recurrence. OTT was performed 14 years later when she was 31 years old, although the grafting of nine fragments of ovarian cortex has not yet

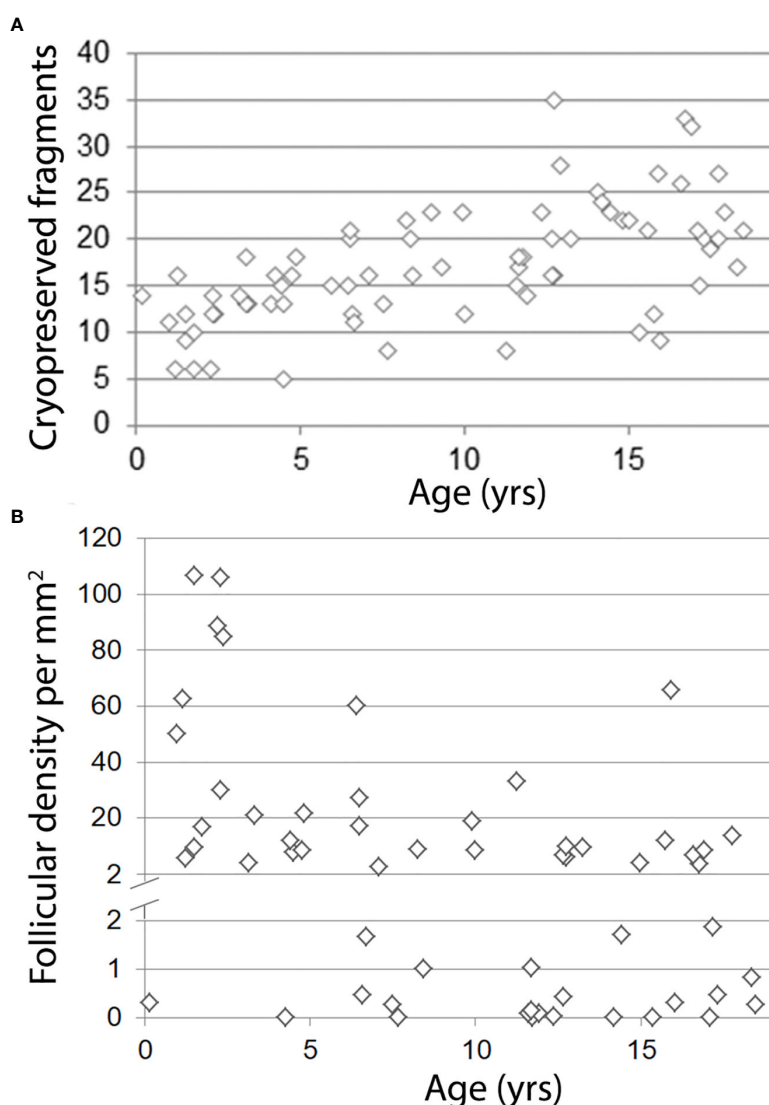


FIGURE 2

Correlation between age and number of cryopreserved fragments (A) or density of primordial follicles (B). A: $R^2 = 0.36$; $p < 0.001$, B: $R^2 = 0.21$; $p < 0.001$.

resulted in a pregnancy. Another patient gave birth through egg donation without undergoing OTT. This patient declined transplantation to avoid another surgical procedure.

Discussion

OTC is still considered an experimental procedure in most countries (3). However, in the last decade, OTC has become the standard care for fertility preservation in both pre- and postpubertal female patients in several countries, including the USA, Israel, Denmark, Norway, and France (23). Additionally, for prepubertal girls, OTC represents the only option for fertility preservation.

Currently, both OTC and OTT procedures are considered safe for adults and children (10). Many young patients who have undergone OTC are still at a young age and have not yet reached a stage where they intend to use the transplantation of thawed ovarian tissue. In our study,

only one patient who had undergone OTC during infancy requested OTT. Despite the recovery of hormonal function, pregnancy has not been achieved after three attempts of *in vitro* fertilization. In Strasbourg University Hospitals, four adult patients have undergone OTT, resulting in two pregnancies [one reported in (24) and one not yet reported].

The results of both university hospitals are quite similar in several aspects of OTC, except for the proportion of malignancies versus non-malignant conditions, the type of ovariectomy (partial bilateral in Strasbourg versus total unilateral in Reims), and the death rate. Non-malignant conditions, such as hemoglobinopathies, accounted for 29% of the total cohort, which is higher compared to several reports (e.g., 16% to 25%) (6, 15, 25–27). This higher proportion of non-malignant conditions in Strasbourg (38%) is due to the collaboration with units of hematopoietic stem cell transplantation (HSCT).

The mean age of our population is 9.3 years, which is lower compared to recent reports where the range is between 11 and 13

years (15, 20, 27, 28). In some recently reported pediatric cohorts, the mean age was even lower, ranging from 6.9 to 7.5 years, but these cohorts included only patients under 14 (28) or 15 years (6), respectively. At the time of the study, the patients' ages ranged from 2 to 33 years, with a mean of 15.4 years. Out of 72 patients, 14 were older than 18 years (19%), and only 5 were older than 23 years (7%). Forty-seven patients were prepubertal at the time of OTC, and 22 were postpubertal, while no information was found for 3 patients regarding hormonal status. Among the prepubertal girls at the time of OTC, 15 remained prepubertal at the time of the study (mean age = 7.6 years), 10 died, 18 needed hormone replacement therapy (HRT), and 2 patients experienced spontaneous puberty. In the postpubertal group at the time of OTC, out of 22 patients, 5 died, and for 6 patients, no information was found regarding hormonal status. Among the remaining 11 postpubertal patients, 10 were under HRT and 1 recovered and had a normal hormonal status.

The size of ovarian tissue fragments is an important parameter for OTC, as smaller sizes have an adverse effect on the graft follicle pool after OTT due to increased activation and loss, known as the "burn-out" effect (29, 30). In our case, the fragments ranged from 3 to 5 mm in size with a thickness of 1 to 2 mm, which is comparable to other studies in children (6) but smaller than reported in other studies (up to 20–30 mm) [reviewed in (31)]. Follicular density is also an important parameter that influences the duration and function of the grafted fragments (32, 33). It is estimated that the majority of primordial follicles are lost during the procedure, particularly after grafting (34). In our study, follicular density, as expected, was highest in younger patients (0–5 years old). The pediatric population in our study represents 38.5% of the total OTC cases, which is consistent with other larger studies (i.e., 40.5%) (6). No complications related to OTC were noted in our cohort.

Conclusion

The evolving landscape of pediatric clinical oncology demands ongoing advancements, driven by improved survival rates, which create an ethical obligation for clinicians to provide fertility preservation options. When young patients necessitate highly gonadotoxic chemotherapy or radiotherapy, OTC emerges as the sole viable technique to consider. Our findings contribute to the existing understanding of OTC in the pediatric population, and further follow-up studies will offer additional insights into the long-term outcomes of this approach for very young patients. To minimize the risk of POI resulting from gonadotoxic therapies, it is recommended that OTC be proposed to all high-risk girls and young women, but only after ensuring that parents and patients have been fully informed about the procedure's risk/benefit ratio.

Data availability statement

The original contributions presented in the study are included in the article/supplementary material. Further inquiries can be directed to the corresponding author.

Ethics statement

Ethical review and approval was not required for the study on human participants in accordance with the local legislation and institutional requirements. Written informed consent from the participants' legal guardian/next of kin was not required to participate in this study in accordance with the national legislation and the institutional requirements. This study was exempt from institutional review board approval according to French Law No. 2004-800 of 6 August 2004 on Bioethics whereby it is stated that OTC is part of patient care.

Author contributions

MG-G, BD, and MT planned the study. FB, AL, and GH performed ovarian tissue retrieval. MT, LL-F, CG, A-SC, IL, and BD cryopreserved ovarian tissue. PQ, GA, and AD performed histological analysis. MG-G, MT, and BD analyzed and collected data, and drafted the paper. CPa and CPL addressed patients for CTO. CR, OP, and GH performed gynecologic and obstetrics follow-up of the patients. All authors contributed to the article and approved the submitted version.

Funding

The work reported in study was funded by the French Ministry of Health.

Acknowledgments

The authors are grateful to all patients who benefited from ovarian tissue cryopreservation and follow-up in the Reproductive Biology Laboratory-CECOS of Reims and Strasbourg University Hospitals. We are grateful to Prof. Catherine Poirot for critically reading the manuscript and all members of the lab for stimulating discussions during the preparation of this report.

Conflict of interest

The authors declare that the research was conducted in the absence of any commercial or financial relationships that could be construed as a potential conflict of interest.

Publisher's note

All claims expressed in this article are solely those of the authors and do not necessarily represent those of their affiliated organizations, or those of the publisher, the editors and the reviewers. Any product that may be evaluated in this article, or claim that may be made by its manufacturer, is not guaranteed or endorsed by the publisher.

References

- Lam CG, Howard SC, Bouffet E, Pritchard-Jones K. Science and health for all children with cancer. *Science* (2019) 363(6432):1182–6. doi: 10.1126/science.aaw4892
- Dolmans MM, von Wolff M, Poirot C, Diaz-Garcia C, Cacciottola L, Boissel N, et al. Transplantation of cryopreserved ovarian tissue in a series of 285 women: a review of five leading European centers. *Fertil Steril* (2021) 115(5):1102–15. doi: 10.1016/j.fertnstert.2021.03.008
- Fabbri R, Vicenti R, Magnani V, Paradisi R, Lima M, De Meis L, et al. Ovarian tissue cryopreservation and transplantation: 20 years experience in Bologna University. *Front Endocrinol (Lausanne)* (2022) 13:1035109. doi: 10.3389/fendo.2022.1035109
- Yding Andersen C, Mamsen LS, Kristensen SG. FERTILITY PRESERVATION: Freezing of ovarian tissue and clinical opportunities. *Reproduction* (2019) 158(5):F27–34. doi: 10.1530/REP-18-0635
- Matthews SJ, Picton H, Ernst E, Andersen CY. Successful pregnancy in a woman previously suffering from β -thalassaemia following transplantation of ovarian tissue cryopreserved before puberty. *Minerva Ginecol* (2018) 70(4):432–5. doi: 10.23736/S0026-4784.18.04240-5
- Poirot C, Brugieres L, Yakouben K, Prades-Borio M, Marzouk F, Lambert G, et al. Ovarian tissue cryopreservation for fertility preservation in 418 girls and adolescents up to 15 years of age facing highly gonadotoxic treatment. Twenty years of experience at a single center. *Acta Obstet Gynecol Scand* (2019) 98(5):630–7. doi: 10.1111/aogs.13616
- Poirot C, Guerin F, Yakouben K, Prades M, Martelli H, Brugieres L. [Ovarian tissue cryopreservation in girls]. *Bull Acad Natl Med* (2013) 197(4–5):887–98.
- Hoekman EJ, Louwe LA, Rooijers M, van der Westerlaken LAJ, Klijn NF, Pilgram GSK, et al. Ovarian tissue cryopreservation: Low usage rates and high live-birth rate after transplantation. *Acta Obstet Gynecol Scand* (2020) 99(2):213–21. doi: 10.1111/aogs.13735
- Bahadur G, Steele SJ. Ovarian tissue cryopreservation for patients. *Hum Reprod* (1996) 11(10):2215–6. doi: 10.1093/oxfordjournals.humrep.a019079
- Feigin E, Abir R, Fisch B, Kravarusic D, Steinberg R, Nitke S, et al. Laparoscopic ovarian tissue preservation in young patients at risk for ovarian failure as a result of chemotherapy/irradiation for primary Malignancy. *J Pediatr Surg* (2007) 42(5):862–4. doi: 10.1016/j.jpedsurg.2006.12.041
- Poirot CJ, Martelli H, Genestie C, Golmard J-L, Valteau-Couanet D, Helardot P, et al. Feasibility of ovarian tissue cryopreservation for prepubertal females with cancer. *Pediatr Blood Cancer* (2007) 49(1):74–8. doi: 10.1002/pbc.21027
- Revel A, Revel-Vilk S, Aizenman E, Porat-Katz A, Safran A, Ben-Meir A, et al. At what age can human oocytes be obtained? *Fertil Steril* (2009) 92(2):458–63. doi: 10.1016/j.fertnstert.2008.07.013
- Oktay K, Oktay O. Fertility preservation medicine: a new field in the care of young cancer survivors. *Pediatr Blood Cancer* (2009) 53(2):267–73. doi: 10.1002/pbc.22003
- Jadoul P, Dolmans M-M, Donnez J. Fertility preservation in girls during childhood: is it feasible, efficient and safe and to whom should it be proposed? *Hum Reprod Update* (2010) 16(6):617–30. doi: 10.1093/humupd/dmq010
- Fabbri R, Vicenti R, Macciocia M, Pasquinelli G, Lima M, Parazza I, et al. Cryopreservation of ovarian tissue in pediatric patients. *Obstet Gynecol Int* (2012) 2012:910698. doi: 10.1155/2012/910698
- Michaelli J, Weintraub M, Gross E, Ginosar Y, Ravitsky V, Eizenman E, et al. Fertility preservation in girls. *Obstet Gynecol Int* (2012) 2012:139193. doi: 10.1155/2012/139193
- Babayev SN, Arslan E, Kogan S, Moy F, Oktay K. Evaluation of ovarian and testicular tissue cryopreservation in children undergoing gonadotoxic therapies. *J Assist Reprod Genet* (2013) 30(1):3–9. doi: 10.1007/s10815-012-9909-5
- Wallace WHB, Smith AG, Kelsey TW, Edgar AE, Anderson RA. Fertility preservation for girls and young women with cancer: population-based validation of criteria for ovarian tissue cryopreservation. *Lancet Oncol* (2014) 15(10):1129–36. doi: 10.1016/S1470-2045(14)70334-1
- Abir R, Ben-Aharon I, Garor R, Yaniv I, Ash S, Stemmer SM, et al. Cryopreservation of in vitro matured oocytes in addition to ovarian tissue freezing for fertility preservation in paediatric female cancer patients before and after cancer therapy. *Hum Reprod* (2016) 31(4):750–62. doi: 10.1093/humrep/dew007
- Jensen AK, Rechner C, Macklon KT, Iversen MRS, Birkebæk N, Clausen N, et al. Cryopreservation of ovarian tissue for fertility preservation in a large cohort of young girls: focus on pubertal development. *Hum Reprod* (2017) 32(1):154–64. doi: 10.1093/humrep/dew273
- Armstrong AG, Kimler BF, Smith BM, Woodruff TK, Pavone ME, Duncan FE. Ovarian tissue cryopreservation in young females through the Oncofertility Consortium's National Physicians Cooperative. *Future Oncol* (2018) 14(4):363–78. doi: 10.2217/fon-2017-0410
- Rodriguez-Wallberg KA, Marklund A, Lundberg F, Wikander I, Milenkovic M, Anastacio A, et al. A prospective study of women and girls undergoing fertility preservation due to oncologic and non-oncologic indications in Sweden-Trends in patients' choices and benefit of the chosen methods after long-term follow up. *Acta Obstet Gynecol Scand* (2019) 98(5):604–15. doi: 10.1111/aogs.13559
- Oktay K, Harvey BE, Partridge AH, Quinn GP, Reinecke J, Taylor HS, et al. Fertility preservation in patients with cancer: ASCO clinical practice guideline update. *J Clin Oncol* (2018) 36(19):1994–2001. doi: 10.1200/JCO.2018.78.1914
- Pellerin M, Garbin O, Teletin M, Lecointre L, Akladios C, Pirrello O. Ovarian cortex transplantation. *J Minim Invasive Gynecol* (2020) 27(6):1253. doi: 10.1016/j.jmig.2019.12.007
- Lotz L, Barbosa PR, Knorr C, Hofbeck L, Hoffmann I, Beckmann MW, et al. The safety and satisfaction of ovarian tissue cryopreservation in prepubertal and adolescent girls. *Reprod BioMed Online* (2020) 40(4):547–54. doi: 10.1016/j.rbmo.2020.01.009
- Rowell EE, Corkum KS, Lutz TB, Laronda MM, Walz AL, Madonna MB, et al. Laparoscopic unilateral oophorectomy for ovarian tissue cryopreservation in children. *J Pediatr Surg* (2019) 54(3):543–9. doi: 10.1016/j.jpedsurg.2018.06.005
- Chambon F, Brugnon F, Grèze V, Grémeau A-S, Pereira B, Déchelotte P, et al. Cryopreservation of ovarian tissue in pediatric patients undergoing sterilizing chemotherapy. *Hum Fertil (Camb)* (2016) 19(1):23–31. doi: 10.3109/14647273.2016.1151561
- Ruan X, Cheng J, Du J, Jin F, Gu M, Li Y, et al. Analysis of fertility preservation by ovarian tissue cryopreservation in pediatric children in China. *Front Endocrinol (Lausanne)* (2022) 13:930786. doi: 10.3389/fendo.2022.930786
- Gavish Z, Peer G, Roness H, Cohen Y, Meirou D. Follicle activation and 'burn-out' contribute to post-transplantation follicle loss in ovarian tissue grafts: the effect of graft thickness. *Hum Reprod* (2014) 29(5):989–96. doi: 10.1093/humrep/deu015
- Kawamura K, Cheng Y, Suzuki N, Deguchi M, Sato Y, Takae S, et al. Hippo signaling disruption and Akt stimulation of ovarian follicles for infertility treatment. *Proc Natl Acad Sci USA* (2013) 110(43):17474–9. doi: 10.1073/pnas.1312830110
- Diaz AA, Kubo H, Handa N, Hanna M, Laronda MM. A systematic review of ovarian tissue transplantation outcomes by ovarian tissue processing size for cryopreservation. *Front Endocrinol (Lausanne)* (2022) 13:918899. doi: 10.3389/fendo.2022.918899
- Rozen G, Sii S, Agresta F, Gook D, Polyakov A, Stern C. Ovarian tissue grafting: Lessons learnt from our experience with 55 grafts. *Reprod Med Biol* (2021) 20(3):277–88. doi: 10.1002/rmb2.12380
- Schmidt KL, Byskov AG, Nyboe Andersen A, Muller J, Yding Andersen C. Density and distribution of primordial follicles in single pieces of cortex from 21 patients and in individual pieces of cortex from three entire human ovaries. *Hum Reprod* (2003) 18(6):1158–64. doi: 10.1093/humrep/deg246
- Roness H, Meirou D. FERTILITY PRESERVATION: Follicle reserve loss in ovarian tissue transplantation. *Reproduction* (2019) 158(5):F35–44. doi: 10.1530/REP-19-0097